Emphysematous Pyelonephritis

Lisa Hui, Medical Student IV, MBA and Jinichi Tokeshi MD, Associate Clinical Professor at the University of Hawaii

Abstract

Emphysematous pyelonephritis is a rare, severe, necrotizing form of renal infection characterized by the presence of gas within the renal parenchyma or perinephric space.[1] In patients suspected of emphysematous pyelonephritis, computed tomography scan should be done promptly. Based on the available data and this case, surgical intervention appears to be the preferred treatment.

Emphysematous pyelonephritis is a rare, severe, necrotizing form of renal infection characterized by the presence of gas within the renal parenchyma or perinephric space.[1] Since the first case of pneumaturia reported in 1898, approximately 168 cases have been reported.[2] Mortality rate ranges from 7 to 90%.[1,2,3] This report illustrates the case of a patient with unilateral emphysematous pyelonephritis caused by *Escherichia coli* (*E. coli*), who recovered after a nephrectomy.

Case Report

A 62-year-old Japanese female with diabetes mellitus (DM) type 2 for 22 years, presented with one week of fever, chills, generalized body ache, and altered mental status. She also had dysuria, polyuria, polydypsia, dyspnea, mild epigastric pain, nausea, and vomiting. She had not taken her insulin for one week.

On physical exam, patient was lethargic but easily arousable. Vital signs included blood pressure 90/48, pulse rate 128/min, respiratory rate 28/min, and temperature 100F. Arterial blood gas revealed a pH of 7.45, pCO2 of 26.3, pO_2 of 65, bicarbonate 19, and oxygen saturation 94% on room air. The patient was obese and dehydrated. Cardiovascular exam revealed tachycardia. Lung exam revealed bilateral coarse crackles. Abdominal exam revealed a flat abdomen and the presence of bowel sounds. The abdomen was soft, non-tender, and without palpable masses. Skin exam revealed no crepitus.

Initial studies included a white cell count of 24.8 x10^9/L with 23% bands, 70% neutrophils, and 6% lymphocytes, and a platelet count of 91 x10^9/L. Chemistries included a serum sodium 116 mg/dl, potassium 3.6 mg/dl, chloride 87 mg/dl, bicarbonate 20 mg/dl, phosphate 1.5 mg/dl, blood urea nitrogen 36 mg/dl, creatinine 2.1 mg/dl, and plasma glucose 625 mg/dl. Urinalysis revealed a specific gravity ≤1.005, glucose ≥1000, trace ketones, moderate amount of leukocyte esterase, 20-50 WBC/hpf, and a moderate amount of bacteria. Chest x-ray revealed bilateral pulmonary edema. Abdominal x-rays in the supine and decubitus views revealed a nonspecific bowel gas pattern suggesting ileus. Urine culture grew >100,000 colonies/ml *E. coli*, and blood cultures grew *E. coli*, sensitive to all of the drugs tested.

The patient was admitted to the intensive care unit and managed for presumed urosepsis and diabetic ketoacidosis. She developed septic shock and was intubated for labored breathing. She was empirically started on levofloxacin and gentamycin. Infectious disease consultant assisted with the choice of antibiotic regimen, which included ampicillin, aztreonam, and trovafloxacin. Yet the patient continued to have fevers to 102F and developed acute respiratory distress syndrome. Platelet count fell to 21 x10^9/L. Serum creatinine rose to 4.2 mg/dl. The ultrasound of the kidneys on day 4 revealed no hydronephrosis and that upper pole of right kidney was obscured by echoes and shadowing suggesting air. The computed tomography (CT) scan of the abdomen with contrast (figure 1) on day 7 revealed a gas-filled mass, possible abscess, at the posterior aspect of the right kidney with displacement of Gerota's fascia and inflammation extending into the retroperitoneal space. The diagnosis of emphysematous pyelonephritis was made based on the CT scan results.

Because the patient's condition continued to decline on medical management, surgical options were explored. Percutaneous drain-

Figure 1.

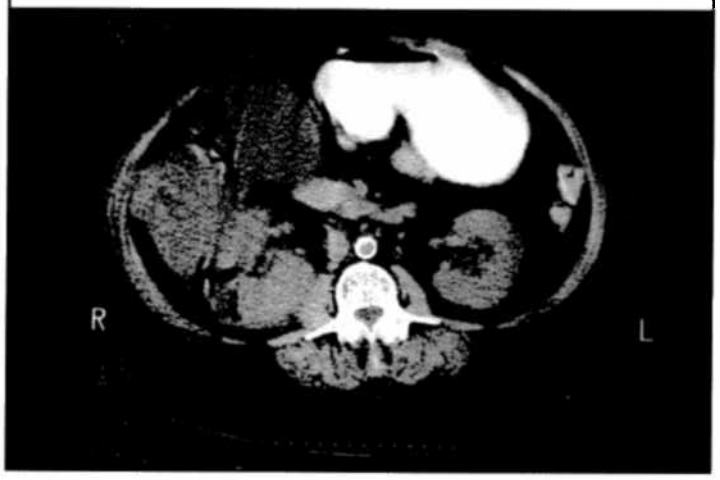

Correspondence to:
Jinichi Tokeshi, MD
1451 South King Street, Suite 209
Honolulu, HI 96814
(808) 949-6221

age was considered, but there did not appear to be a well-defined, loculated area. The right nephrectomy was done on day 8. The nephrectomy was done retroperitoneally with a right flank incision. Gerota's fascia was filled with pus. Grossly, the entire kidney including cortex, medulla, and pelvis were hemorrhagic and necrotic with no normal tissue. Microscopically, there were extensive areas of acute inflammation, necrosis, and hemorrhage. The parenchyma contained small irregular spaces. In some areas, the perinephric soft tissue appeared to have separated from the renal parenchyma. Culture from the right kidney grew *E.coli* sensitive to all antibiotics tested.

Postopertively, the patient's condition improved and she was discharged from the hospital two weeks later.

Discussion

Emphysematous pyelonephritis is caused by organisms which cause urinary tract infection. *E. coli* accounts for 60% of the cases. Other pathogens include *Enterobacter aerogenes*, *Klebsiella pneumonia*, *Proteus mirabilis*, and *Pseudomonas aeroginosa*. Cases of *Candida* spp, *Cryptococcal neoformans*, *Clostridium septicum*, and *Streptococcus* sp have also been reported.[1,4] Infections are polymicrobial in 14-19% of cases.[4] Eighty percent of the cases are unilateral.[3] It is more common in women than men (2:1). Risk factors are diabetes (70 to 90% of cases), obstruction, and urinary tract infection with gas-forming microorganisms.[1,3,5] The main factors contributing to gas formation are enhanced CO_2 production from severe infection and hypoperfusion resulting in decreased gas elimination.[5] Presenting symptoms are similar to those of upper urinary tract infection, including fever, chills, nausea, and vomiting. Infrequently, there is crepitation over the thigh or flank area from extension of the emphysematous pyelonephritis into the perinephric space and retroperitoneum.[1] According to Wan et al, serum creatinine level was the single most significant variable in predicting outcome.[2]

Imaging studies of the upper tract should be performed in patients with upper urinary tract infection who do not respond after 72 hours of intravenous antibiotic therapy.[1] Abdominal x-rays reveal renal parenchymal gas in only 33% of cases, and the gas may be difficult to distinguish from bowel gas.[3,7] Ultrasound depicts gas as high-amplitude echoes with distal shadowing containing low-level echoes and reverberations ("dirty" shadowing or "comet" sign). Likewise, the renal parenchymal gas may be difficult to distinguish from the surrounding bowel gas and from renal calculi.[7] CT scan is the most reliable imaging tool in evaluating emphysematous pyelonephritis.[7,9] CT scan is useful in distinguishing emphysematous pyelonephritis from emphysematous pyelitis (gas localized to the renal collecting system), which has a different pathogenesis and prognosis.[1] Contrast should be used with caution especially in diabetic patients with compromised renal function.

The overall mortality rate for emphysematous pyelonephritis remains high. In patients treated medically, the mortality rate is 60% if the gas is confined to the renal parenchyma, and 80% if the gas has extended into the perinephric space. In patients treated with surgical intervention (percutaneous drainage or nephrectomy), mortality rate is ≤20%. Of the 15 bilateral cases reported, there were 7 deaths.[3] Note that the data is based on a small number of reported cases, and that the patients managed medically may include a larger portion of the more severely ill patients who were deemed poor surgical candidates.[8] Nevertheless, surgical intervention appears to result in a lower mortality rate. Surgical intervention is especially indicated in patients who do not respond to medical therapy and in patients with obstructive emphysematous pyelonephritis.[4]

Conclusion

Emphysematous pyelonephritis is a rare, severe, necrotizing form of renal infection characterized by the presence of gas within renal parenchyma or perinephric space. They present as severe cases of upper urinary tract infection. In those patients with abdominal x-ray or ultrasound suggesting emphysematous pyelonephritis, or who do not respond after 72 hours of appropriate antibiotic therapy, a CT scan of the upper uninary tract is indicated. It is the most reliable tool for diagnosing emphysematous pyelonephritis. The mortality rate for emphysematous pyelonephritis ranges from 7 to 90%. Surgical intervention is associated with lower mortality rate compared to medical management, and appears to be the preferred treatment.

References

1. Patterson JE, Andriole VT. Bacterial urinary tract infections in diabetes. *Infectious Disease Clinics of North America* 1997; 11: 735-751.
2. Wan YL, Lo SK, Bullard MJ, Chang PL, Lee TY. Predictors of outcome in emphysematous pyelonephritis. *The Journal of Urology* 1998; 159: 369-373.
3. Stein JP, Spitz A, Elmajian DA, Esrig D, Freeman JA, Grossfeld GD, Ginsberg DA, Skinner DG. Bilateral emphysematous pyelonephritis: a case report and review of the literature. *Urology* 1996; 47: 129-134.
4. Punnose J, Yahya TM, Premchandran JS, Ahmed HF. Emphysematous pyelonephritis responding to medical therapy. *International Journal of Clinical Practice* 1997; 51: 468-470.
5. Hildebrand TS, Nibbe L, Frei U, Schindler R. Case Report: Bilateral emphysematous pyelonephritis caused by *Candida* infection. *American Journal of Kidney Diseases* 1999; 33: E10.
6. Chen MT, Huang CN, Chou YH, Huang CH, Chiang CP, Liu GC. Percutaneous drainage in the treatment of emphysematous pyelonephritis: 10-year experience. *The Journal of Urology* 1997; 157: 1569-1573.
7. Joseph RC, Amendola MA, Artze ME, Casillas J, Jafri SZH, Dickson PR, Morillo G. Genitourinary tract gas: imaging evaluation. *RadioGraphics* 1996; 16: 295-308.
8. Wan YL, Lee TY, Bullard MJ, Tsai CC. Acute gas-producing bacterial renal infection: correlation between imaging findings and clinical outcome. *Radiology* 1996; 198: 433-438.
9. Shokeir AA, El-Azab M, Mohsen T, El-Diasty T. Emphysematous pyelonephritis: a 15-year experience with 20 cases. *Urology* 1997; 49: 343-346.