

The Open Access Israeli Journal of Aquaculture – Bamidgeh

As from **January 2010** The Israeli Journal of Aquaculture - Bamidgeh (IJA) will be published exclusively as **an on-line Open Access (OA)** quarterly accessible by all AquacultureHub (<http://www.aquaculturehub.org>) members and registered individuals and institutions. Please visit our website (<http://siamb.org.il>) for free registration form, further information and instructions.

This transformation from a subscription printed version to an on-line OA journal, aims at supporting the concept that scientific peer-reviewed publications should be made available to all, including those with limited resources. The OA IJA does not enforce author or subscription fees and will endeavor to obtain alternative sources of income to support this policy for as long as possible.

Editor-in-Chief

Dan Mires

Editorial Board

Sheenan Harpaz Agricultural Research Organization
Beit Dagan, Israel

Zvi Yaron Dept. of Zoology
Tel Aviv University
Tel Aviv, Israel

Angelo Colorni National Center for Mariculture, IOLR
Eilat, Israel

Rina Chakrabarti Aqua Research Lab
Dept. of Zoology
University of Delhi

Ingrid Lupatsch Swansea University
Singleton Park, Swansea, UK

Jaap van Rijn The Hebrew University
Faculty of Agriculture
Israel

Spencer Malecha Dept. of Human Nutrition, Food
and Animal Sciences
University of Hawaii

Daniel Golani The Hebrew University of Jerusalem
Jerusalem, Israel

Emilio Tibaldi Udine University
Udine, Italy

Copy Editor

Ellen Rosenberg

Published under auspices of
**The Society of Israeli Aquaculture and
Marine Biotechnology (SIAMB),
University of Hawaii at Manoa Library**

and
**University of Hawaii Aquaculture
Program** in association with
AquacultureHub

<http://www.aquaculturehub.org>



UNIVERSITY
of HAWAII
MĀNOA
LIBRARY



AquacultureHub
educate • learn • share • engage

ISSN 0792 - 156X

© Israeli Journal of Aquaculture - BAMIGDEH.

PUBLISHER:
Israeli Journal of Aquaculture - BAMIGDEH -
Kibbutz Ein Hamifratz, Mobile Post 25210,
ISRAEL

Phone: + 972 52 3965809

<http://siamb.org.il>

RAPID WOUND HEALING IN AFRICAN CATFISH, *CLARIAS GARIEPINUS*, FED DIETS SUPPLEMENTED WITH ASCORBIC ACID

Gregoria Erazo-Pagador*

*Aquaculture Department, Southeast Asian Development Center,
Tigbauan, Iloilo, Philippines 5021*

Mohd Shariff Din

*Faculty Veterinary Medicine and Animal Science, Universiti Putra, Malaysia 43400,
UPM Serdang, Selangor, Malaysia*

(Received 20.3.01, Accepted 5.5.01)

Abstract

Wound healing in African catfish, *Clarias gariepinus*, fed diets supplemented with ascorbic acid was studied under laboratory conditions. Fish weighing approximately 80-110 g were stocked in 500 l aquaria in a static water system and fed one of five test diets containing different levels of microencapsulated ascorbic acid (0, 0.06, 0.10, 0.30 and 0.70 g AsA/100 g feed). After two weeks, all experimental fish were wounded by making a 1 x 1 cm dorso-lateral incision above the lateral line of the fish. Wounded tissues were sampled for histopathological analysis 4, 8, 24, 48 and 96 hours, 6, 8, 10, 12 and 14 days after making the incision. There were significant differences in weight gain, specific growth rate (SGR) and feed conversion ratio among the dietary treatments. Weight gain and SGR of fish fed the ascorbic acid free diet were lower than those of fish fed diets supplemented with ascorbic acid. The wound healing response showed a direct correlation to ascorbate level in the diet. Fibroblasts were present at 96 h irrespective of the ascorbic acid level. As 14 days, fish fed no ascorbic acid had some regeneration of muscle tissues, whereas fish fed diets containing supplemental ascorbic acid had a normal epidermis, dermis and muscle structure. There was no mortality during the experimental period, and fish fed ascorbic acid free diets did not exhibit any deficiency signs. Results of this study indicate that about 0.10-0.70 g AsA/100 g feed is needed for wound repair in African catfish.

* Corresponding author. Email: gep@aqd.seafdec.org.ph

Introduction

African catfish, *Clarias gariepinus*, is one of the most popular freshwater fishes cultured in southeast Asia. It is a fast-growing omnivore that matures and reproduces in captivity throughout the year. It is readily accepted in local markets and has excellent culture characteristics such as easy reproduction, high fecundity, good feed conversion rate, high tolerance to a wide range of environmental conditions and high resistance to stress and infections.

Ascorbic acid (vitamin C) is an essential water-soluble vitamin for fishes (Lim and Lovell, 1978; Halver, 1979; MacConnell and Barrows, 1993). It is a cofactor in the transformation of proline to hydroxyproline, which is a constituent of collagen and thus necessary for the formation of connective tissues, bone matrix and scar tissue in wound repair (Halver, 1982; Jauncey et al., 1985). It plays an important role in wound healing in coho salmon and rainbow trout (Halver et al., 1969), channel catfish (Lim and Lovell, 1978) and tilapia (Jauncey et al., 1985). However, this vitamin is very unstable and easily affected by temperature, oxygen, pH, light and time (NRC, 1983). Studies on wound healing have been performed on coldwater fishes (Halver et al., 1969, 1975; Halver, 1972) and warmwater fishes such as channel catfish, *Ictalurus punctatus* (Lim and Lovell, 1978) and cultured tilapia, *Oreochromis niloticus* (Trewavas; Jauncey et al., 1985).

The present study aimed at determining the effect of microencapsulated ascorbic acid (ENCAP C) on simple wound healing in *C. gariepinus* through sequential histopathology.

Materials and Methods

Experimental animals, facilities and rearing methods. Samples of African catfish (body weight 80-110 g) were obtained from Beranang, Selangor, Malaysia. These were stocked in a 1 ton tank for acclimation, and treated with potassium permanganate (10 ppm, 30 minutes) as a prophylaxis against bacterial, fungal and parasitic infestations (Mahajan and Agrawal, 1980). To deplete ascorbate in their tissues, the experimental fish were fed an ascorbic acid free basal diet (38%

crude protein) for two weeks. After this acclimatization, 11 individuals were stocked in each of 15 randomly arranged glass aquaria (500 l capacity) in a static water system. The system was aerated and totally covered with black plastic to minimize the aggressive behavior (cannibalism) of the catfish. The aquaria were cleaned daily to minimize algal and fungal growth that could provide a source of ascorbic acid (Lim and Lovell, 1978). Water temperature ranged from 28 to 30°C.

Diet preparation and feeding. Five isonitrogenous and isocaloric diets were prepared after the Universiti Putra Malaysia (UPM) formulation for catfish diet (Table 1). The experimental diets (Diets 2-5) were supplemented with various levels (0.06, 0.10, 0.30 and 0.70 g/100 g) of microencapsulated ascorbic acid (ENCAP C). The basal (unsupplemented) diet served as the control. The ingredients were homogenized using a Hobart mixer, pelleted and air dried. The dry diets were sealed in black plastic bags and stored at -10°C. Prior to feeding, the diet was removed from the storage freezer and kept in a refrigerator (3-4°C). Proximate analysis of the diets was according to AOAC (1984) standard methods. The catfish were fed twice daily at 3% of their body weight for 28 days. One half of the ration was given at 08:00 and the other half at 17:00.

Wounding and sampling. After two weeks of feeding with the test diets, the catfish were wounded, using the modified technique used by Jauncey et al. (1985). Each fish was anesthetized with tricaine methanesulfonate (MS 222, 100-200 ppm) for 5-10 minutes prior to making the incision. A 1 x 1 cm dorso-lateral incision above the lateral line was made with a number 22 surgical blade. All fish were wounded on the same day. Feeding continued for 28 days. Sequential histopathological changes were studied wherein three fish from each treatment were sacrificed 4, 8, 24, 48, and 96 hours and 6, 8, 10, 12, and 14 days after wounding. The wounds and about 2 mm of the surrounding tissue were excised from the fish and fixed in 10% buffered formalin. The tissue was decalcified in 4N formic acid for 12 h, processed, embedded in paraffin wax, sectioned at 5 µm, and stained with hema-

Table 1. Composition of experimental diets.

	<i>Treatment</i>				
	1	2	3	4	5
<i>Ingredient (g/100 g dry diet)</i>					
Fish meal	50	50	50	50	50
Soya bean flour	28	28	28	28	28
Corn flour	10	10	10	10	10
Wheat flour	7	7	7	7	7
Tapioca	3	2.94	2.90	2.70	2.30
Vitamin premix ¹	1	1	1	1	1
Mineral mix ²	1	1	1	1	1
Ascorbic acid ³	0	0.06	0.10	0.30	0.70
Total	100	100	100	100	100
<i>Proximate analysis (%)</i>					
Crude protein	51.9	51.3	50.9	50.7	50.7
Crude fat	5.6	5.6	5.5	5.4	5.4
Crude fiber	8.3	8.4	8.4	8.7	8.6
Ash	9.1	9.1	8.9	8.7	8.6
NFE	25.1	25.6	26.3	27.0	27.1

¹ Vitamin premix (g per 100 g): vitamin K₃ 0.5, choline 25, niacin 5, riboflavin 1, pyridoxine 1, thiamine 1, calcium D-pantothenate 2.5, biotin 0.001, folacin 0.25, vitamin B₁₂ 0.001. The following vitamins were supplied in IU/100g: vitamin A 275,000 IU, vitamin D 55,000 IU, vitamin E 2500 IU.

² Mineral mix (g/100 g): Mn 4.5, Zn 15.7, Fe 10.0, I 0.119, Cu 1.5.

³ An encapsulated commercial ascorbic acid (ENCAP C) produced by Gold Coin, Singapore.

toxylin and eosin (Humason, 1979) for histological analysis.

Statistical analysis. Experimental data were statistically evaluated using one-way analysis of variance and Duncan's multiple range test to determine differences among means ($p < 0.05$) of weight gain, feed conversion rate and specific growth rate (SAS, 1982).

Results

The structure of catfish skin, described by Grizzle and Rogers (1976), consists of three

layers: the epidermis, the dermis and the hypodermis. The epidermis is a stratified squamous epithelial layer comprising the mucus cells or goblet cells and large eosinophilic club cells. The dermis lies beneath the epidermal layer and is divided into stratum compactum and stratum spongiosum. The hypodermis consists of a fine network of loose connective tissues beneath the stratum compactum and muscle tissues.

Results show that there was an apparent migration of epidermis passing in and under

the dermis to cover the denuded tissues at 4 h (Fig. 1). There was extensive spongiosis of the dermal layer. Hemorrhages occurred between muscle bands but with no apparent external hemorrhages on the skin. Myopathy was seen at and around the site of the wound and a few macrophages were found in the injured area. After 8 h, the migrating epidermis joined the breach and became spongiotic. Active myophagia were observed. At 24 h, the newly joined epidermis had thickened but the dermal layer remained spongiotic (Fig. 2). The reunited epidermis at the wound site had an irregular surface and the muscle tissues were fragmented.

In tissues of fish fed diets without ascorbic acid, the epidermis was detached from the dermal layer surrounding the wound until 48 h. In contrast, in fish fed diets supplemented with ascorbic acid, there was no apparent separation of the dermal and epidermal layers. The injured muscles were regenerating.

At 96 h after wounding, the reunited epidermis at the wound site was attached to the dermal layer. Light fibroblast proliferation was seen in the dermal layer. Atrophic muscle fibers were also present. In all tissues of fish fed diets with ascorbic acid the fibroblastic response was heightened, with a proliferation of the collagen fibers, epidermal thickening (Fig. 3) and presence of club and mucus cells, whilst in the dermal region large clumps of sequestered melanin pigments were fully restored and granulation tissue was observed. There was also an irregular arrangement of fibroblasts in the dermal layer extending to join fibrous replacement tissues in the underlying muscle layer. The hypodermal layer remained incomplete.

At 6 days, the epidermis and dense dermal layer were well united but the dermis still contained numerous fibroblasts at the wound site. Melanin pigments were also present in fish fed the diet without supplemental ascorbic acid.

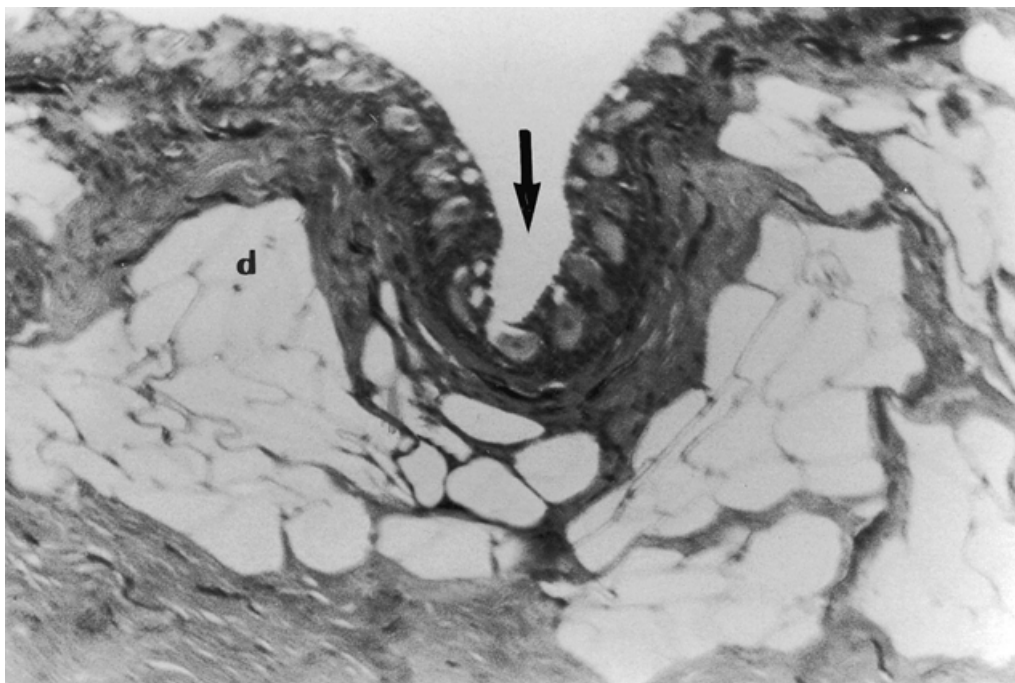


Fig. 1. Section of migrating epidermis (arrow) four hours after wounding. The dermal layer (d) was spongiotic.

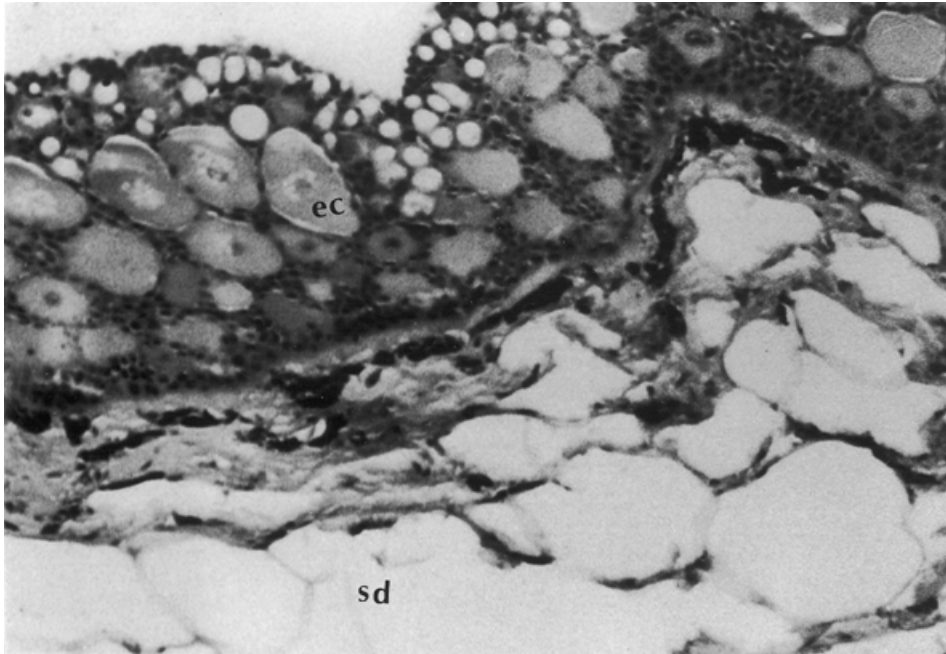


Fig. 2. Presence of large epidermal cells (ec) at 24 hours with spongiotic dermal (sd) layer.

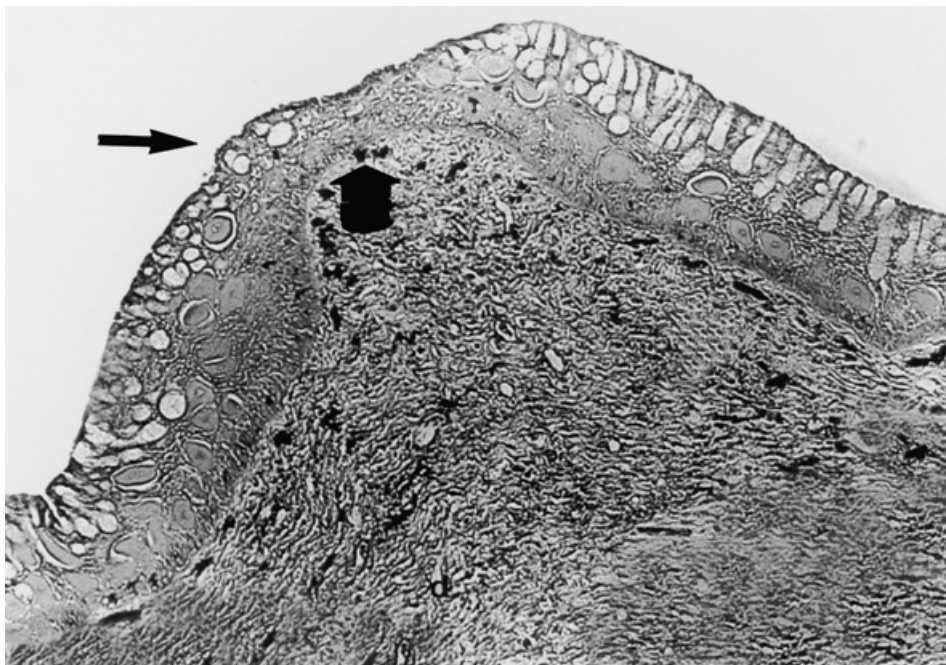


Fig. 3. Wound at 96 hours (fish fed 0.30 mg ascorbic acid/100 g feed). Epidermal thickening (long arrow), melanin pigmentation (wide arrow).

Extensive areas of muscle atrophy were also present in the wound area. There was a well-defined border between incised and newly regenerated muscle fibers in fish fed 0.06 g AsA. Granulation tissues became more compact with the disappearance of macrophages. There was an apparent external scar on the wound of fish fed 0.70 g AsA when fibroplasias took place, forming a mesh of collagen in the healing wound (Fig. 4). Large aggregations of melanin were present in the epidermal layer with a well-defined border between incised and newly regenerated muscle fibers.

The epidermal surface was smooth and paved on day 8. Fibroblasts were found in the hypodermal area in fish fed the diet without ascorbic acid. Muscle fibers beneath the dermis were still regenerating and were immature, whereas in fish fed diets supplemented

with ascorbic acid, melanin pigment was also present and the dense collagen had been replaced with light collagen fibrils. New muscle bundles became more distinct and extensive.

Ten days after wounding, the epidermal layers thickened due to an increase in the malpighian cell numbers and abundance of mucus and club cells. The wound of fish fed the diet supplemented with 0.06 g ascorbic acid was clearly reinstated with the presence of fibroblasts at the cut edge of the dermal layer; there were melanin pigments beneath the epidermal layer (Fig. 5).

At 12 days after wounding, the granulation tissue had mostly disappeared. The hypodermal layer in fish fed the 0.06 g AsA/100 g feed was partially repaired. Muscle tissues were regenerating, though immature.

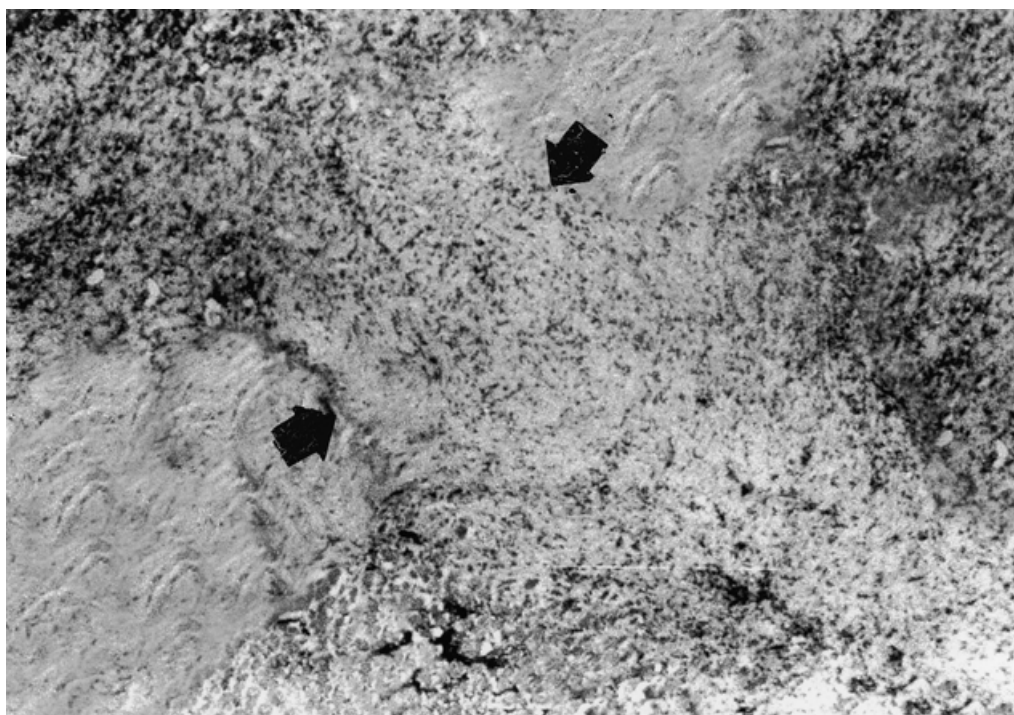


Fig. 4. Healing wound at 6 days (fish fed 0.70 g ascorbic acid/100 g feed). The granulation tissue contains delicate regenerating collagenic fibers along the cut collagenous dermal layer (arrows).



Fig. 5. Healing wound at 10 days (fish fed 0.06 g ascorbic acid/100 g feed). The epidermis is clearly reinstated and collagen fibrils (wide arrow) appear at the cut edge of the dermal layer. Melanin pigments (thin arrow) are present.

After 14 days, the epidermal layer, irrespective of ascorbic acid levels, healed to normal, including the skin where the wound was inflicted. Mucus and club cells were abundant. Muscle tissues of fish fed the diet without supplemental ascorbic acid were still regenerating (Fig. 6) while those fed diets with ascorbic acid were normal in structure (Fig. 7).

Table 2 shows the weight gain, feed conversion ratio and specific growth rate of fish fed diets with or without supplemental ascorbic acid. Mean weight gains and specific growth rates increased significantly with increases in ascorbic acid level of the diets. Differences were significant in weight gains of fish fed ascorbic acid (36.04 ± 3.78 - 43.65 ± 0.16) and fish fed no ascorbic acid (32.62 ± 1.75). Fish fed no ascorbic acid had lower food conversion (2.58 ± 0.14) than fish fed diets supplemented with ascorbic acid. No signs of pathology were observed in fish fed ascorbic acid deficient diets.

Discussion

Wound healing experiments have been carried out in rainbow trout (Halver et al., 1969), channel catfish (Lim and Lovell, 1978) and Nile tilapia (Jauncey et al., 1985). These workers found that wound healing is impaired in fish fed ascorbic acid free diets, whereas fish fed diets with dietary ascorbic acid had more rapid and complete wound healing.

Ascorbic acid has important biological and metabolic functions, particularly in the biosynthesis of collagen. Healing of wounds is characterized by synthesis of collagen (Ashley et al., 1975). It is well established that ascorbic acid is required for the hydroxylation of prolyl and lysyl residues during collagen biosynthesis (Sato et al., 1982). The results of the present study indicate that fish given diets with ascorbic acid have denser collagen and more fibrous granulation tissue at the epidermal and dermal layers than fish fed diets without ascorbic acid. Thus, the delay in wound healing in fish fed

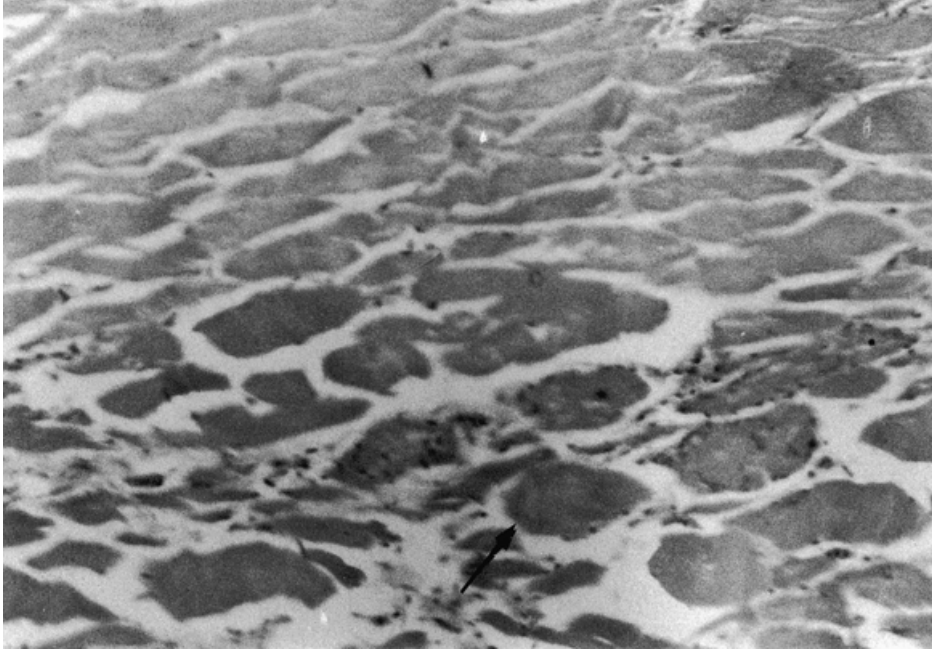

Fig. 6. At day 14 (fish fed no ascorbic acid), muscle fibers (arrow) are still regenerating.

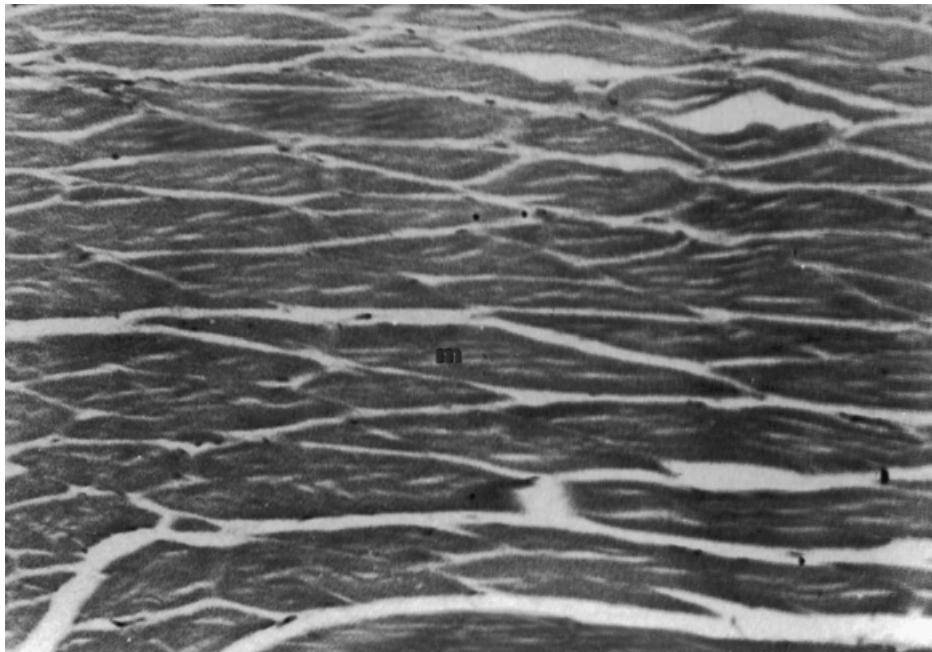


Fig. 7. At day 14 (fish fed 0.06 g ascorbic acid/100 g feed), normal muscle structure (m) is restored.

Table 2. Percent weight gain, specific growth rate (SGR) and food conversion ratio (FCR) of *Clarias gariepinus* fed different levels of ascorbic acid.

Treatment	Initial weight (g)	Final weight (g)	Weight gain ¹ (%)	SGR ² (%)	FCR ³
1	84.13±0.48 ^a	111.57±2.60 ^a	32.62±1.75 ^a	1.0±0.06 ^a	2.58±0.14 ^a
2	85.30±0.78 ^a	116.04±2.50 ^a	36.04±3.78 ^{ab}	1.1±0.07 ^a	2.38±0.26 ^{ab}
3	88.68±1.21 ^b	121.34±0.67 ^b	36.83±1.90 ^{abc}	1.12±0.02 ^{abc}	2.29±0.12 ^{ab}
4	89.05±0.30 ^b	124.65±0.24 ^{bc}	39.97±0.73 ^{abc}	1.21±0.02 ^{bc}	2.10±0.04 ^{ab}
5	89.99±0.14 ^b	129.28±0.33 ^c	43.65±0.16 ^c	1.3±0.09 ^c	1.92±0.01 ^b

Values within a column sharing the same superscript are not significantly different at $p < 0.05$.

¹ Weight gain (%) = (final wt - initial wt)/initial wt × 100

² Specific growth rate (%) = (ln mean final wt - ln mean initial wt)/ no. of culture days × 100

³ Feed conversion ratio = dry weight feed (g)/wet weight gain (g)

ascorbic acid free diets can be attributed to the induced collagen synthesis. These results conform with findings in coho salmon (Halver et al., 1969), rainbow trout (Halver, 1972), channel catfish (Lim and Lovell, 1978) and tilapia (Jauncey et al., 1985).

The histopathology of wound healing in fish fed ascorbic acid has been described in coho salmon (Halver et al., 1969), rainbow trout (Halver, 1972), channel catfish (Lim and Lovell, 1978) and tilapia (Jauncey et al., 1985). Healing of wounds starts with migration of epithelial cells. In this study, the complete closure of the incision took four hours, as opposed to five hours in the experiments of Jauncey et al. (1985). The epidermal closure of the wound is important in the prevention of fluid loss by the tissues which may cause an osmoregulation imbalance that allows bacterial penetration (Bereiter-Hahn, 1986). Rapid epidermal covering of wounds is also necessary for the early appearance of mucus cells within the healing epidermis; these mucus cells may have antibodies for the immune system (Fletcher and Grant, 1969).

Epidermal thickening above the wound is typical for wound repairs. This precedes the

repair of dermal collagen. Melanin pigments in catfish skin occurred concurrently with repair of the dermis at 96 h irrespective of ascorbic acid levels. Iger and Abraham (1990) presumed that melanin from the dermal melanocytes has a bacterial-infection preventive role after wounding. Ellis (1977) also reported that melanin granules, free or in macrophages, may have bactericidal properties. The repair of the injured epidermis was completed before the repair of the dermis; this could be explained by considering the role of the basement membrane and dermal fibers during regeneration (Jauncey et al., 1985).

In this study, pathological changes were observed in the muscle sections irrespective of ascorbic acid levels. There was muscle atrophy in *C. gariepinus* fed diets deficient in ascorbic acid, though none in fish fed diets with supplemented ascorbic acid. Similar findings have been reported by other authors, revealing that the effects of trauma in wound healing were apparent enough to make muscle atrophy and lesion extensive (Halver et al., 1969; Halver, 1972; Ashley et al., 1975; Lim and Lovell, 1978).

In the present study, external scar formation appeared six days after wounding. Lim and Lovell (1978) found that all wounded fish showed external wound healing after 10 days irrespective of ascorbic acid levels. This can be attributed to the size and age of the fish, degree of damage, temperature, nutrition and stress factors that affect wound healing in fishes (Halver et al., 1975).

Eya (1996) found that "broken-skull disease" and higher mortality in *C. gariepinus* are caused by ascorbic acid deficient diets. This phenomenon holds true in the present study where *C. gariepinus* fed the ascorbic acid deficient diet had slow growth and poor feed conversion. Works by Durve and Lovell (1982) and Li and Lovell (1985) for *Ictalurus punctatus*, Hilton et al. (1978), Halver (1979) and Sato et al. (1982) for *Salmo gairdneri*, and Mahajan and Agrawal (1980) for *Cirrhina mrigala* obtained similar results in terms of ascorbic acid requirements of other fish species.

Eya and Mgbenka (1990) reported poor growth, hemorrhages and tissue erosion on the edges of the dorsal fins, operculum and pectoral spine in African catfish fed an ascorbic acid deficient diet. Korean rockfish fed an ascorbic acid deficient diet had scoliosis, exophthalmia and fin hemorrhage (Lee et al., 1998). Aguirre and Gaitlin (1999) reported that red drum had reduced weight, lordosis, scoliosis and loss of equilibrium when fed an ascorbic acid deficient diet.

Supplemental ascorbic acid is very unstable in fish diets and considerable losses have been reported after processing and storage (Hilton et al., 1977; Sandness and Utne, 1982). Ascorbic acid is extremely sensitive to heat and easily degraded during feed processing and storage. The leaching rate of ascorbic acid is rapid in water since it is highly water soluble. This may lead to an insufficient supply of ascorbic acid, reducing the performance of aquatic animals. Many attempts have been made to produce stabilized derivatives of ascorbic acid. Microencapsulation of free ascorbic acid increases stability to the rigors of pelleting and storage and reduces leaching in water but does not reduce digestibility. Microencapsulated vitamin C has been introduced to the market

recently under the trade name ENCAP C-70. It has a minimum ascorbic acid content of 70%. After one month of feed storage, ascorbic acid retention in the diet was about 60.7%. Leaching losses of ENCAP C were reported to be 13.0% (Gold Coin, Singapore).

Histological examination revealed that, at 14 days after wounding, fish fed diets without ascorbic acid had a normal epidermis and dermis but muscle tissues were still regenerating, whereas fish fed diets containing ascorbic acid had a normal epidermis, dermis and muscle tissues. The present study suggests that more than 0.06 g AsA/100 g of microencapsulated dietary ascorbic acid is needed for faster wound repair in African catfish.

Rapid wound healing is especially important in the intensive culture of African catfish. This species behaves aggressively, has no scales and has pectoral spines that can inflict wounds especially at high stocking densities. Based on these results, ascorbic acid in microencapsulated form can effect fast wound repair in *C. gariepinus* at 0.10 g AsA/100 g.

Acknowledgments

Our sincere thanks to Mr. Rosenio R. Pagador for support and assistance in this study, Ms. Milagros Castaños, Ms. Mae Catacutan and Mr. Nelson Golez for helpful comments on the first draft and the Microtechnique Staff of SEAFDEC/AQD for their technical assistance. This research was supported by International Developmental Research Centre, Canada (IDRC).

References

- Aguirre P. and D.M. Gaitlin III, 1999. Dietary vitamin C requirement of red drum *Sciaenops ocellatus*. *Aqua. Nutr.*, 5:247-249.
- AOAC, 1984. *Official Methods of Analysis*. 14th ed. Assoc. Official Analytical Chemists, Washington, DC. 1141 pp.
- Ashley L.M., Halver J.E. and R.R. Smith, 1975. Ascorbic acid deficiency in rainbow trout and coho salmon and effect on wound healing. pp. 769-786. In: W.B. Ribelin and G. Migaki (eds.). *The Pathology of Fishes*. Univ. Wisconsin Press, Madison, Wisconsin.
- Bereiter-Hahn J., 1986. Epidermal cell migra-

- tion and wound repair. pp. 443-471. In: J. Bereitner-Hahn, A.G. Matoltsy and K.S. Richards (eds.). *Biology of the Integument. Vol. 2 - Vertebrates*. Springer, Heidelberg.
- Durve V.S. and R.T. Lovell**, 1982. Vitamin C and disease resistance in channel catfish (*Ictalurus punctatus*). *Can. J. Fish. Aquat. Sci.*, 39:948-951.
- Ellis A.E.**, 1977. The leucocytes of fish: A review. *J. Fish Biol.*, 11:453-491.
- Eya J.C.**, 1996. "Broken-skull disease" in African catfish *Clarias gariepinus* is related to a dietary deficiency of ascorbic acid. *J. World Aquac. Soc.*, 27:493-498.
- Eya J.C. and B.O. Mgbenka**, 1990. Preliminary studies on ascorbic acid requirement of African catfish *Clarias gariepinus* Teugeks 1984. *J. Aqua. Sci.*, 5:65-72.
- Fletcher T.C. and P.T. Grant**, 1969. Immunoglobulins in the serum and mucus of the plaice. *Biochem. J.*, 115:65.
- Grizzle J.M. and W.A. Rogers**, 1976. *Anatomy and Histology of the Channel Catfish*, Auburn Univ., Agric. Exp. Stn., Auburn, Al. 94 pp.
- Halver J.E.**, 1972. The role of ascorbic acid in fish disease and tissue repair. *Bull. Jpn. Soc. Sci. Fish.*, 38:79-92.
- Halver J.E.**, 1979. Vitamin requirements of finfish. pp. 45-48. In: J.E. Halver and K. Tiews (eds.). *Finfish Nutrition and Fishfeed Technology*. Vol. I. Heeneman, Berlin.
- Halver J.E.**, 1982. The vitamins. In: J.E. Halver (ed.). *Fish Nutrition*. Academic Press, New York. 713 pp.
- Halver J.E., Ashley L.M. and R.R. Smith**, 1969. Ascorbic acid requirements of coho salmon and rainbow trout. *Trans. Am. Fish. Soc.*, 98:762-771.
- Halver J.E., Smith R.R., Tolbert B.M. and E.M. Baker**, 1975. Utilization of ascorbic acid in fish. *Ann. NY Acad. Sci.*, 258:81-102.
- Hilton J.W., Cho C.Y. and S.J. Slinger**, 1977. Factors affecting the stability of supplemental ascorbic acid in practical trout diets. *J. Fish. Res. Board Can.*, 34:683-687.
- Hilton J.W., Cho C.Y. and S.J. Slinger**, 1978. Effect of graded levels of supplemental ascorbic acid in practical diets fed to rainbow trout. *J. Fish. Res. Board Can.*, 35:431-436.
- Humason G.L.**, 1979. *Animal Tissue Technique*. W.H. Freeman and Co., San Francisco. 641 pp.
- Iger Y. and M. Abraham**, 1990. The process of skin healing in experimentally wounded carp. *J. Fish Biol.*, 36:421-437.
- Jauncey J., Soliman A.K. and R.J. Roberts**, 1985. Ascorbic acid requirements in relation to wound healing in the cultured tilapia *Oreochromis niloticus* (Trewavas). *Aqua. Fish. Manage.*, 16:139-149.
- Lee K.J., Kim K.W. and S.C. Bai**, 1998. Effects of different dietary levels of L-ascorbic acid on growth and tissue vitamin C concentration in juvenile Korean rockfish, *Sebastes schlegeli* (Hilgendorf). *Aquacult. Res.*, 29:237-244.
- Li Y. and R.T. Lovell**, 1985. Elevated levels of dietary ascorbic acid increase immune response in channel catfish. *J. Nutr.*, 115:123-131.
- Lim C. and R.T. Lovell**, 1978. Pathology of the vitamin C deficiency syndrome in channel catfish (*Ictalurus punctatus*). *J. Nutr.*, 108:1137-1146.
- MacConnell E. and F.T. Barrows**, 1993. Pathological changes associated with vitamin C deficiency in walleyes. *J. Aqua. Ani. Health*, 5:287-293.
- Mahajan C.L. and N.K. Agrawal**, 1980. Nutritional requirements of ascorbic acid by Indian major carp, *Cirrhina mrigala* during early growth. *Aquaculture*, 19:37-48.
- NRC**, 1983. *Nutrient Requirements of Warmwater Fishes*. Natl. Acad. of Sci., Natl. Res. Council, Washington DC, USA. 76 pp.
- Sandness K. and F. Utne**, 1982. Processing loss and storage stability of ascorbic acid in dry fish feed. *Fisk. Dir. Skr. Ser. Ernaering.*, 2:39-44.
- SAS**, 1982. *SAS User's Guide: Statistics*. SAS Inst. Inc., Cary, NC. 584 pp.
- Sato M., Kondo T., Yoshinka R. and S. Ikeda**, 1982. Effect of dietary ascorbic acid levels on collagen formation in rainbow trout. *Bull. Jpn. Soc. Sci. Fish.*, 48:553-556.