



The IJA is a peer-reviewed open-access, electronic journal, freely available without charge to users
-
Produced by the AquacultureHub non-profit Foundation
Sale of IJA papers is strictly forbidden



Common and newly discovered pathogens in the Israeli Mediterranean Sea mariculture

Margarita Smirnov^{1*}, Tamir Ofek¹, Hanna Hershko² and Tetsuzan Benny Ron^{1,3}

¹ *Central Fish Health Laboratory, Fisheries, and Aquaculture, Ministry of Agriculture and Rural Development, Nir David, 1080300 Israel*

² *Veterinary Service, Hadera, Israel*

³ *Intensive Aquaculture Research Station, Fisheries and Aquaculture, Ministry of Agriculture and Rural Development, Ginosar, Israel*

Keywords: annual changes in pathogen composition, fish pathogens, Israeli mariculture, Mediterranean Sea

Abstract

In the last few decades, the farming of different fish species in Israeli mariculture gradually increased. This paper presents the last 15 years' study results that define the most significant fish pathogens and evaluate their seasonal or annual occurrence. During this survey, three new pathogens were detected, described, and entirely or partially characterized (the articles in press).

* Corresponding author. e-mail: ritas@moag.gov.il

Introduction

From the beginning of its foundation, the Israeli fish farming industry chose intensification as the main direction of its development. Two factors influenced this decision: 1) the necessity of maximum land usage; and 2) the shortage of water sources in Israel (Shilo and Sarig, 1989).

The results of the continuous intensification have shown a significant increase in average yield: 10-30 tons per hectare (data from the Association of Israeli Fish Breeders). Such achievement was a limiting factor for further development in conventional ponds and reservoirs. Because of this situation, the Israeli fish industry has invested in developing a marine culture in the Mediterranean Sea. The particular adaptation of offshore cage technology was used because of the very shallow Israeli coastline in the Mediterranean Sea.

Another advancement was establishing hatchery technology for various fish species' larval production (Gordin, 2003). The prevention and effective control of fish disease have significant importance for the achievement of success in the Israeli marine culture.

We aimed to collect essential information about the most current health situation, study the spread and the prevalence of various agents, and evaluate their significance for developing a strategy to decrease the effect of the diseases. This report focuses on the most common pathogens (although three of them are reported for the first time in Israeli farms on the Mediterranean coast) in the different species examined in the Central Fish Health Laboratory in Nir David (CHFL) during a routine inspection or subsequent outbreaks. Finally, we have summarized the current situation.

Diseases of Mariculture Fish

Viral diseases

VNN/VER

Based on significant fish losses and the following scientific publications, the most severe viral disease of cultured marine fishes in Israel is VNN (viral nervous necrosis) caused by betanoviruses. This disease is also named viral encephalopathy and retinopathy. Ucko et al. (2004) reported findings of this virus in Israel from 5 species of fish from 1996 to 2002. The virus was isolated from both sick and healthy fish. Berzak et al. (2019) detected it in wild fish populations and cultured marine fish. In the Mediterranean Israeli farms, the most susceptible species to the virus are hybrid bass and mullet, whereas sea bream and red drum show less susceptibility.

The disease affects these fish from 5-mm larvae to 15 cm juveniles in the hatchery and cages. Mortalities may reach up to 20-80 %. Permissive water temperatures were from 20-25 °C. The fish demonstrated abnormal swimming and were dark in color. PCR and histology identify the virus. Pathological changes were found in the brain and retina (Beraldo et al., 2007). Their nerve cells showed vacuolization and degeneration (**Figure 1**). VNN was not found in fish cultured in cages during the past few years. A few cases of VNN that were diagnosed occurred in juvenile fish in hatcheries.

Lymphocystis

In Israel, more than 20 years ago, the lymphocystis iridovirus was found in two edible fish: the red drum (*Sciaenops ocellatus*) (Colorni and Diamant, 1995) and sea bream (*Sparus aurata*) (Paperna et al., 1982). For the past ten years, most findings have been recorded in early-stage juveniles in the hatchery or cages, and the percentage of affected fish was neglectable- about 0.2 %. Virus infection produces numerous dermal clusters on fins (**Figure 2**). The internal organs of fish were affected rarely. Histology analysis revealed hypertrophic cells surrounded by a thick wall below the epidermis (**Figure 3**). No

mortalities were connected to the presence of lymphocystis, and signs of diseases disappeared during the production period.

Megalocytivirus diseases (RSIV/ISKNV)

In 2013, the first outbreak of megalocytivirus was confirmed in imported red drum (*Sciaenops ocellatus*) and the meager (*Argyrosomus regus*) (data of CFHL). After a long break, new outbreaks of this disease suddenly occurred in November - December 2021 (Smirnov et al., 2021). Surprisingly the disease was found only in gilthead sea bream. This infection was marked by chronic mortality during all growing periods and happened mostly in cages. Fish infected by the virus had profound anemia of gills, enlarged liver, spleen, and kidney. Histopathological analysis revealed giant darkly stained cells (**Figure 3**). Molecular detection was confirmed using PCR (Kurita and Nakajima, 2016).

Bacterial diseases

The Mediterranean Israeli fishery had to cope with several bacterial diseases from its establishment. However, the significance of each disease is variable. Some infectious bacteria can result in mass losses in fish. Others cause chronic disease duration without severe mortality. The third type of bacteria occasionally occurs in stressed fish and could be involved secondarily in outbreaks (Colorni et al., 1981). Some bacterial diseases occasionally occur, such as streptococcosis, mycobacteriosis, and aeromonosis.

Vibriosis

Vibriosis is a significant bacterial disease in Israeli marine cultured fish found in the past five years during examination in CFHL *Vibrio alginolyticus*, *Vibrio harveyi*, *Vibrio cholera*, *Vibrio parahaemolyticus*, and *Vibrio vulnificus* are the most often isolated bacteria from sick fish (Macián et al., 2004). The disease's clinical signs are non-specific: hemorrhages in fins, skin lesions, or exophthalmia. If 15 years ago, the presence of vibrio infections had a seasonal character and occurred in the winter months, the last severe outbreaks happened all year round. Moreover, in most cases, several members of the genus *Vibrio* were simultaneous.

However, one new bacterium, *Vibrio ponticus*, has been isolated in recent years. Fish affected by this new agent had similar clinical signs of infection as the fish with other vibrioses. The first case of *V. ponticus* isolated from sea bream and seawater mussels was reported in Spain (Macián et al., 2004). It was involved in outbreaks of sea bream in the cages in our cases.

Pasteurellosis (Photobacterium damsela ssp. piscicida)

Hybrid bass (*Morone saxatilis* X *Morone chrysops*) was introduced into Israel in 1993 (Nitzan et al., 2001). In Spring 1994, when water temperature rose to 22-24°C, the first outbreak of pasteurellosis happened in a farm located on the coast of the Mediterranean Sea. Then during the next ten years, this bacterium became the most emerging problem of cultured sea fish production. Between 2002 and 2019, the cases of mortalities because of *Photobacterium damsela ssp. piscicida* sharply decreased. However, since the end of 2019, it has returned and probably become an increasing problem in Israeli mariculture again. It is isolated as individually as in mixed infections with *Vibrio* bacteria. Clinical signs of the disease include hyperpigmentation of the skin and enlargement of the spleen and kidney. A 1-2 mm lesion "pseudogranuloma" may be found under microscopic examination (**Figures 4 and 4a**).

Streptococcus iniae

The first case of streptococcus infection on the Israeli Mediterranean coast was recognized in 1995 in cages with sea bass (*Dicentrarchus labrax*) (Coloni). According to surveillance of the research group of Morris Kahn (Berzak et al., 2019), *S. iniae* was found in different marine fish and crustaceans, but the fish mortalities that were directly connected to this bacterium were not established. At the same time, fish cultured in conventional ponds are periodically affected by *Streptococcus iniae* (unpublished data of the CFHL).

Mycobacteriosis

Different species of *Mycobacterium* spp cause the disease. (mainly by *M. marinum*) and has been considered a common problem in some regions of the Mediterranean Sea (Vendramin et al., 2016). In Israel, the first isolation of this bacterium was done in 1990 in the Gulf of Eilat in the Red Sea (Coloni, 1992) and was detected in 18 species of local wild and farm fish (Ucko et al., 2002). As known, the typical clinical signs of this disease are apathy of fish and skin discoloration. The liver, kidney, and spleen have granulomatous lesions (**Figure 5**). However, on the farms of the Mediterranean Sea in the past five years, such cases have occurred only occasionally. Most small fish from hatcheries have been tested before transportation to offshore fish farms and have been pathogen-free for five years.

Aeromonosis

This disease is caused by motile aeromonads such as *Aeromonas hydrophila*, *Aeromonas sobria*, *Aeromonas veronii*, and *A. caviae*. Clinical signs may be external (skin lesions, exophthalmia), internal (abdominal dropsy), or both. In Israeli mariculture, high losses because of aeromonosis are associated with particular stressors such as handling and transportation or abrupt changes in the water quality.

Epitheliocystis agent

This infection in marine fish was found and described by Paperna (1977) and Egusa (1987). Since then, it has been observed in various marine and cultured freshwater fish in Israel. Epitheliocystis is a chlamydia organism affecting epithelial cells of the gills and causing its hypertrophy. Microscopically it looks like spherical bodies filled with included inside cocci (**Figure 6**). Serious infections were seen mainly in young fish of sea bream and mullet. Mixed infections with *Monogenea* result in heavy mortalities. Lately, epitheliocystis infections in juvenile fish are more common.

Parasitic infections

Throughout the history of Israeli mariculture in the Mediterranean Sea, the mortalities caused by different ectoparasites and endoparasites have been observed. Some of them are opportunistic parasites that invade fish during a growing period or when water conditions deteriorate, causing the fish to be stressed and susceptible to infections (Paperna, 1991)

Ectoparasites

Ectoparasitic protozoa

Amyloodinium ocellatum (phylum *Dinoflagellata*) and *Trichodina* ssp. (phylum *Ciliophora*)

These parasites were considered mainly protozoan parasites in Israeli marine fish. Suppose *Trichodina* spp. (**Figure 7**) are ubiquitous cosmopolitan ectoparasites and their

pathological effects depend on density in the cage and the health status of fish. In that case, *Amyloodinium ocellatum* is implicated in mass mortalities of marine fish both in the hatchery and in fish cages (**Figures 8 and 8a**). In the past decade, *Amyloodinium* infections significantly decreased and are rarely found only in the hatchery where they are controlled by treatment.

Ectoparasitic Metazoa

Gill flukes in sea bream, mullet, and bass are widespread in Israeli offshore farming and are considered a significant problem in our aquaculture.

Monogeneans

Diplectanum aequans and *Sparicotyle chrysophrii*

These monogenean parasites result in high mortalities in the Mediterranean fish farms. The monogenean parasites as *Diplectanum aequans* and *Sparicotyle chrysophrii* result in high mortalities in the Mediterranean fish farms. However, in the past three years, monogenean capsalids such as *Neobenedenia girellae* was often identified in sea bream (*Sparus aurata*) (**Figure 9**). The first report of mortality in mullets caused by monogenean capsalids (*Benedenia monticelli*) was published by Paperna et al. (1981). It presents a severe threat to cultured fish due to high pathogenicity. Several cases were reported because of its ability to cause high fish mortality (citations?).

Endoparasites

Microsporidia like agent

In the Mediterranean Sea, a microsporidian infection was described in young gilthead sea bream in 1996 by Abela et al. The parasite was assigned to the *Pleistophora* genus. But until very recently, microsporidia infections were not associated with marine fish cultured in Mediterranean Israeli farms. In the past two years, several cases occurred. The small lesions were observed in the skin of gilthead sea bream and young mullets. Histological analysis revealed microsporidian infections (**Figure 10**). Since the prevalence of the parasite and its infectivity were very low and neglectable, it remains unclassified. After a month, the lesions disappeared, and microsporidia were not discovered.

Myxozoa

Enteromyxum leei

This parasite is an apparent problem in gilthead sea bream since it significantly influences fish production. It causes significant losses and the reduction of growth in surviving fish. (Diamant et al., 1994). However, its influence is minor in the Mediterranean fish farms in Israeli mariculture. Only a few cases of cultured fish outbreaks have been recorded in all surveillance periods.

Polysporoplasma sparidis

It was reported in several countries of the Mediterranean Sea (Sitja-Bobadilla et al., 1995; Bartošová et al., 2013). In Israel, it was first found in the kidney of sea bream in 2006 (Diamant, personal communication). This parasite was not considered a severe problem until 2021. But long-period mortalities were observed throughout the year 2021. Affected fish were infected with various pathogens like *Vibrio* sp., *Photobacterium damsela* ssp. *piscicida*, monogenean flukes, and *Polysporoplasma sparidis* (**Figures 11 and 11a**). After several treatments, mortalities ceased in cages where only bacteria and ectoparasites

were found. Chronic mortality continued in other cages with a high parasite prevalence, resulting in low fish survival. The taxonomic position of the parasite was confirmed with morphological, histological, and molecular analysis (the publication in press).

Digenea

Digenean parasites have not been revealed in sea cages of marine fish along the Mediterranean coast for the past ten years. Only one case was noted in wild *Epinephelus* sp. brought to the CFHL by an angler. A significant amount of digenean eggs were observed in the vessels of gill filaments. These eggs caused severe damage, such as degeneration of lamellae tissue or its necrosis (**Figure 12**). The presumed conclusion was that they were eggs of sanguinicolid, *Cardicola* sp. (Holzer et al., 2007)

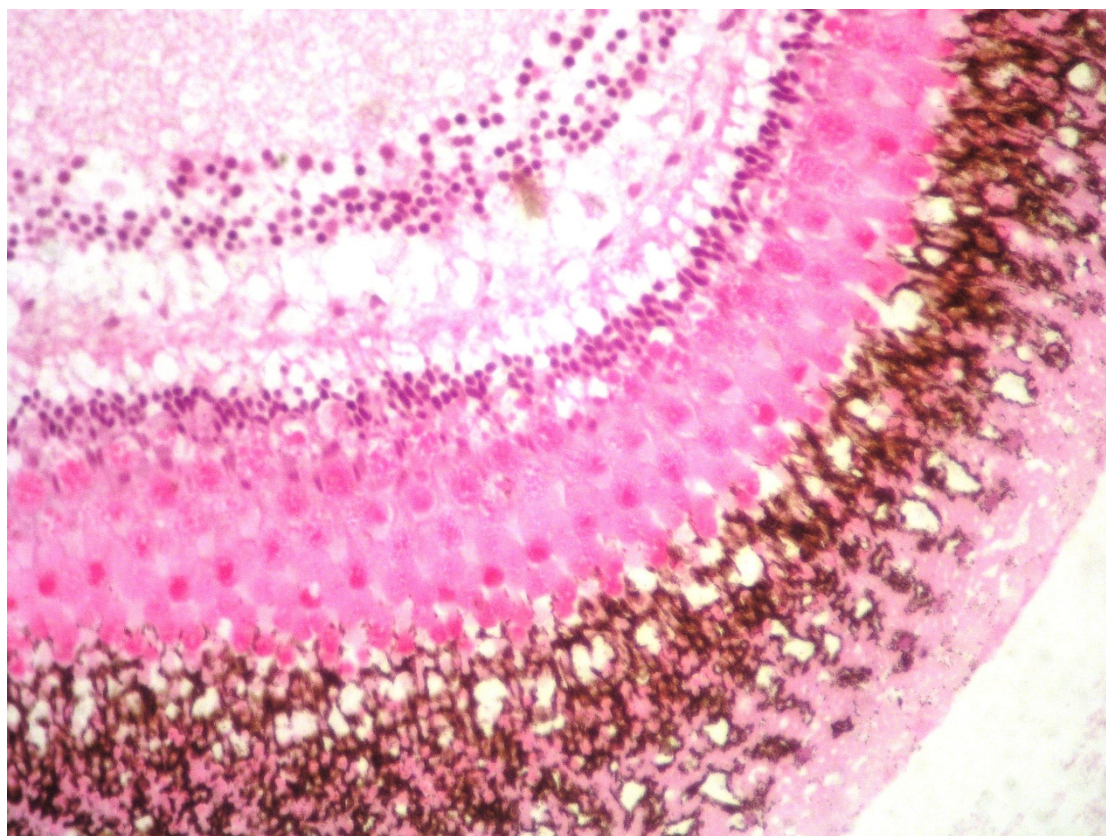


Figure 1 VNN vacuoles in the eye of the red drum (HEX1000)

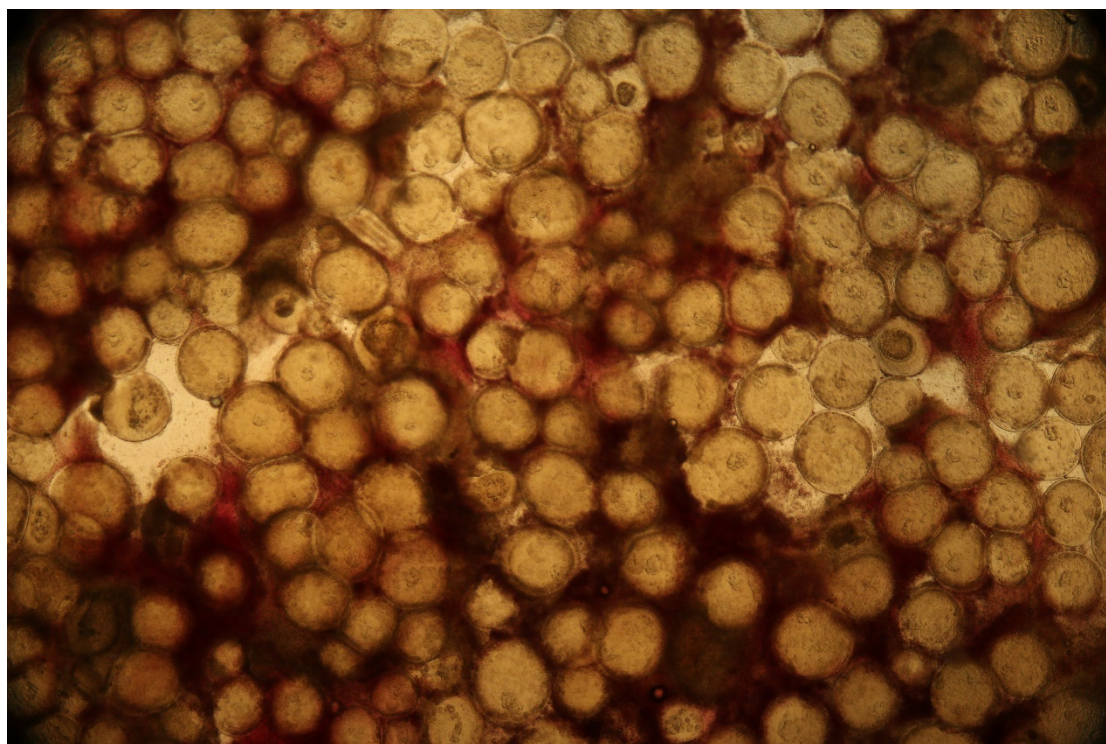


Figure 2 Lymphocystis in sea bream (*Sparus aurata*) skin (light microscopy x100)

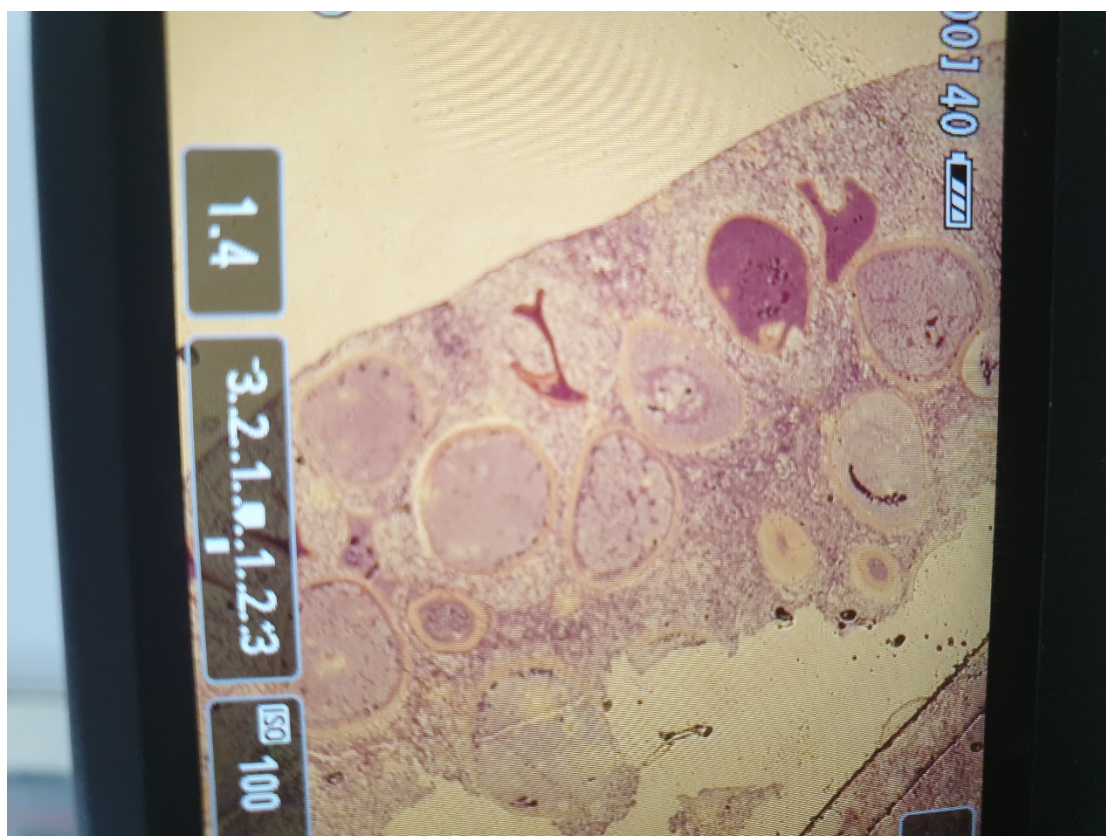


Figure 2a Histology: Hypertrophic cells point in the presence of lymphocystis virus X100.

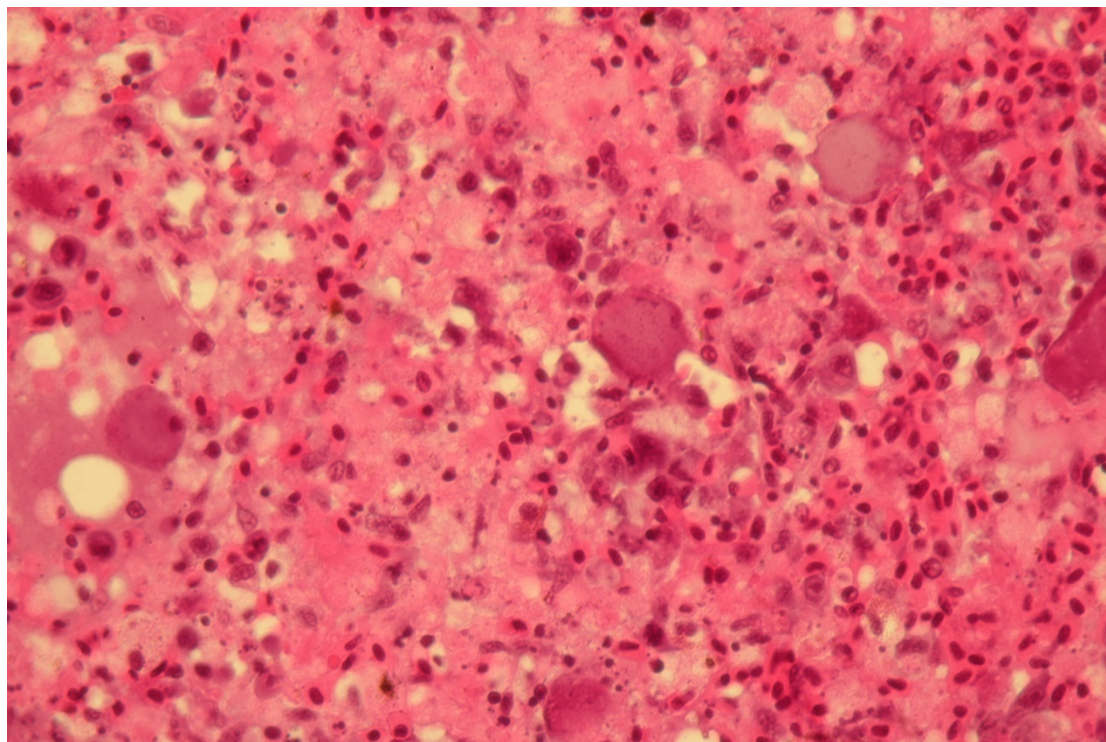


Figure 3 *Megalocytivirus* in meagre x100 (Histology section)

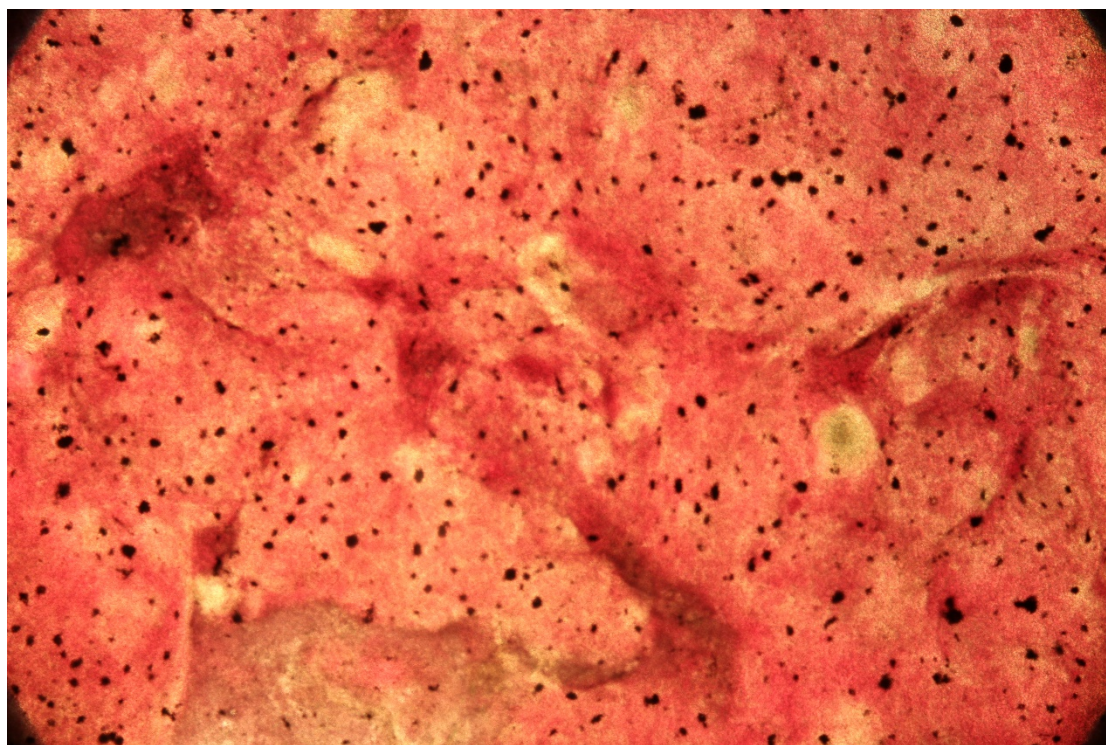


Figure 4 *Photobacterium damsela* ssp. fresh preparation X100

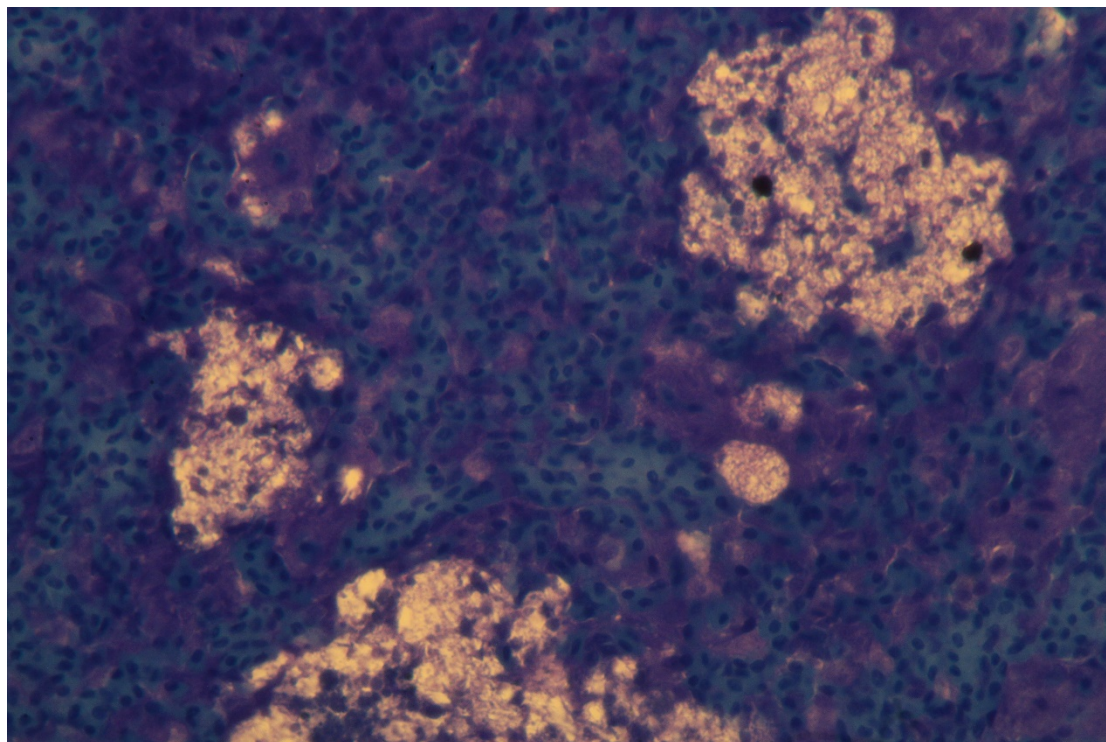


Figure 4a "Pseudogranuloma" (Histology, Toluidine blue, x400)

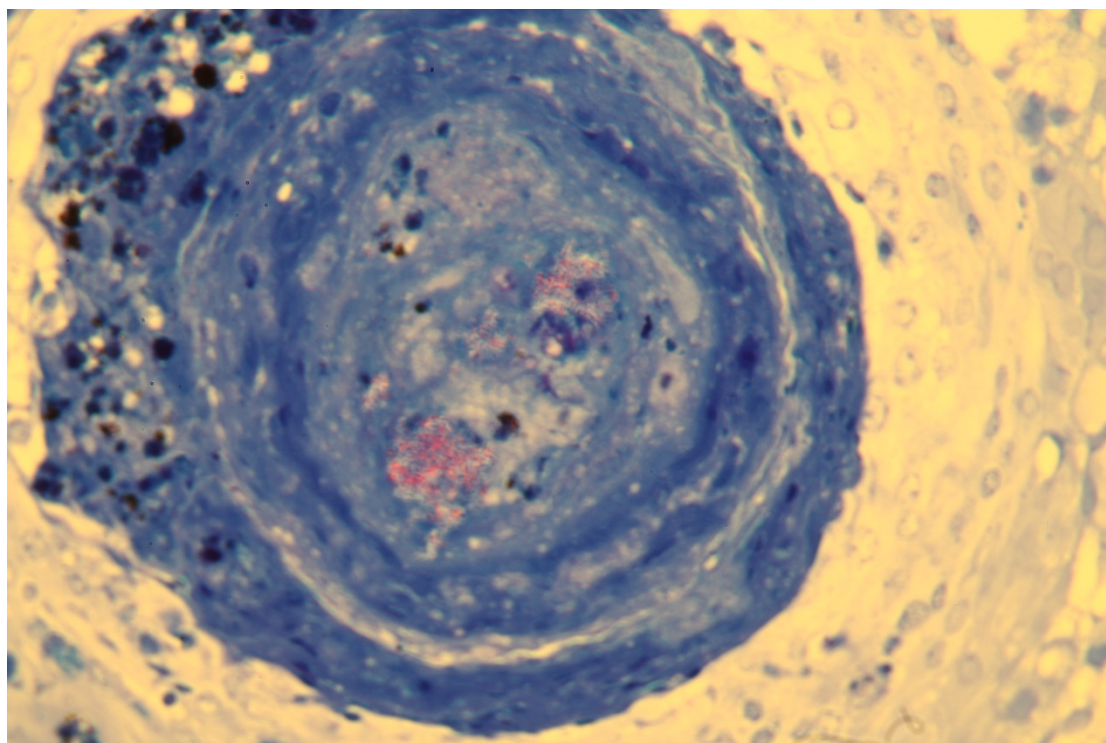


Figure 5 Visceral granulocyte caused by mycobacterium. Necrotic area includes red stained bacteria (Histology, Ziehl Neelsen, X100)

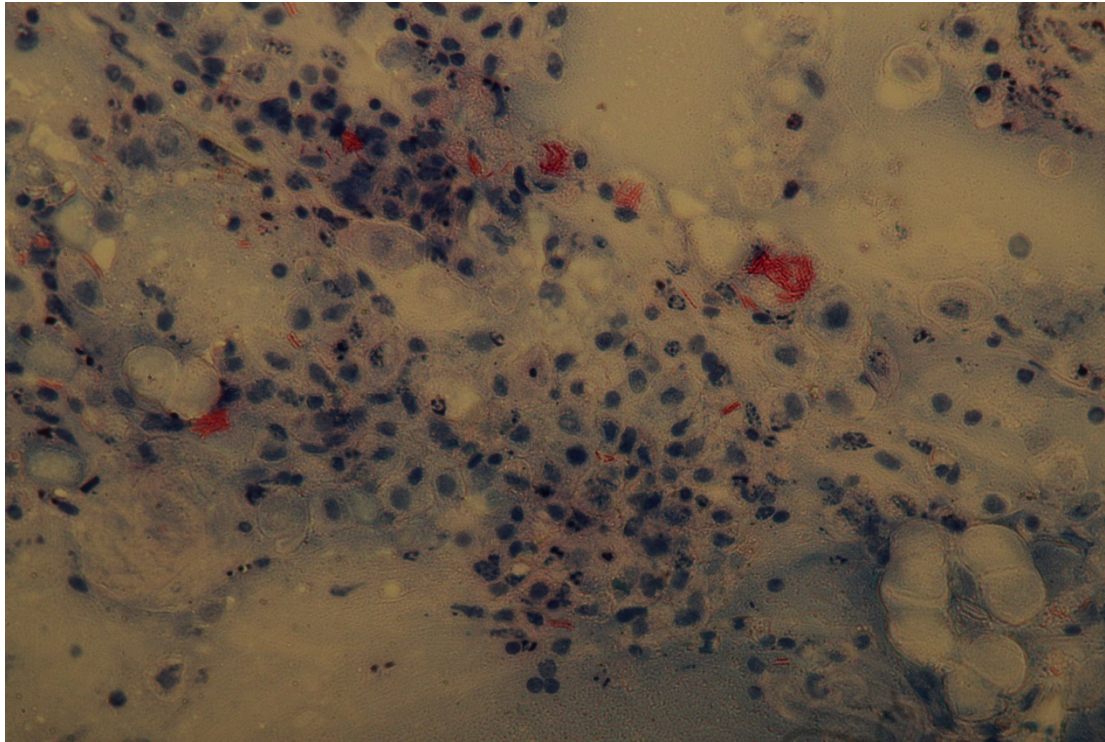


Figure 5a *Mycobacterium* spp. in fingerlings of hybrid bass. Cytology, Ziehl Neelsen x400.

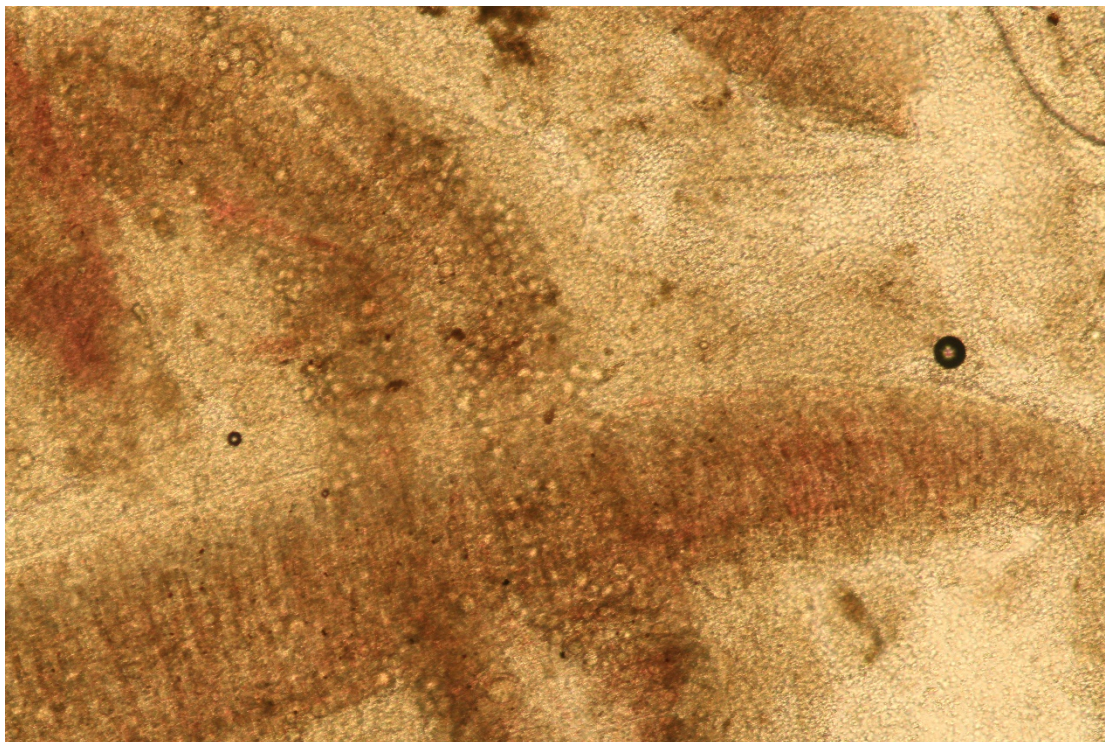


Figure 6 Epitheliocystis in gill (Light microscopy X 100)

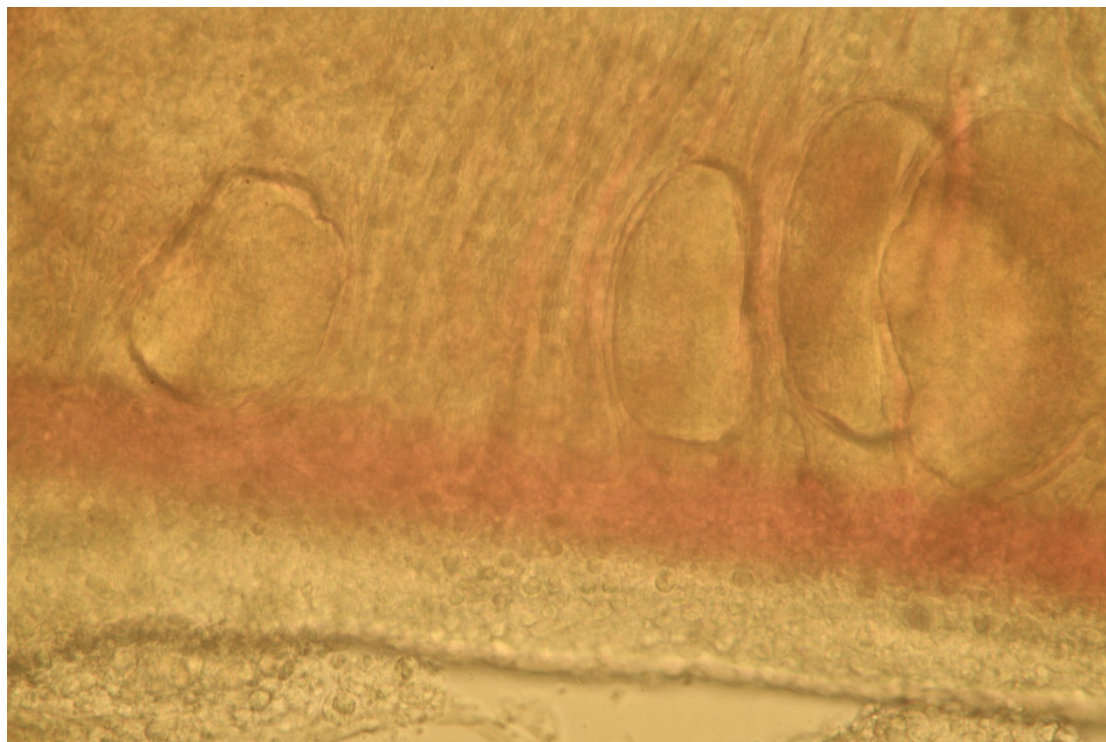


Figure 6a Epitheliocystis in the gill with higher power microscopy view of **Figure 6**




Figure 7 *Trichodina ssp.* at lower power microscopy

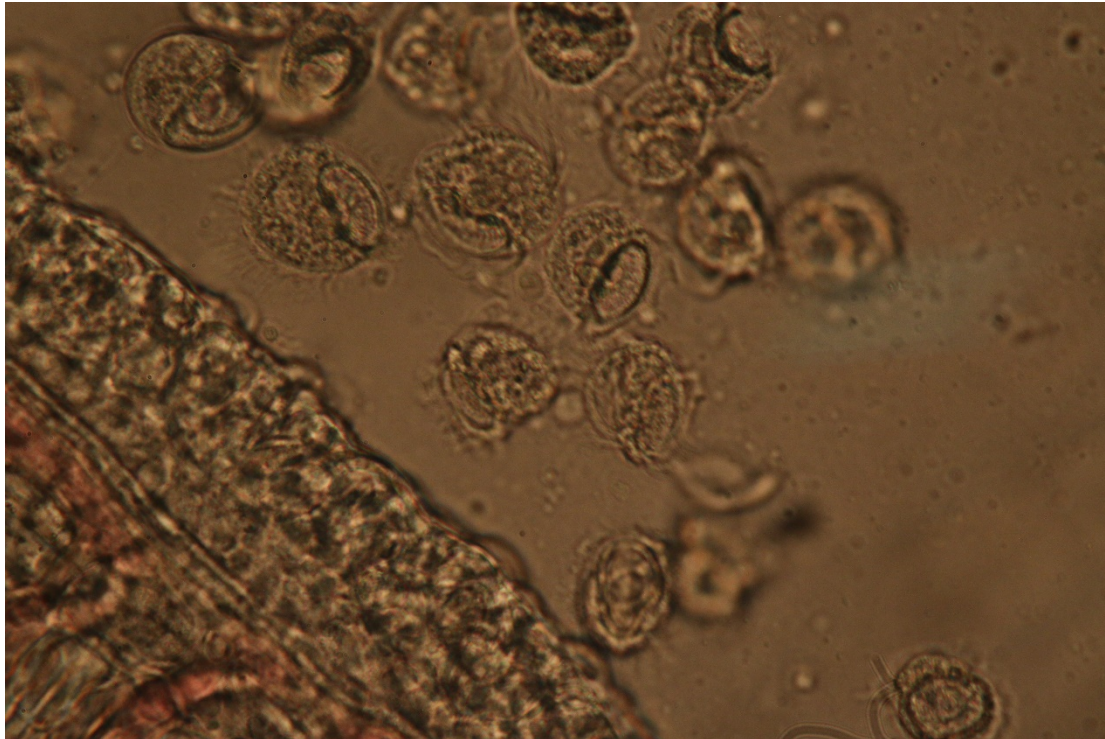


Figure 7a Higher power (X1000) microscopy of **Figure 7**

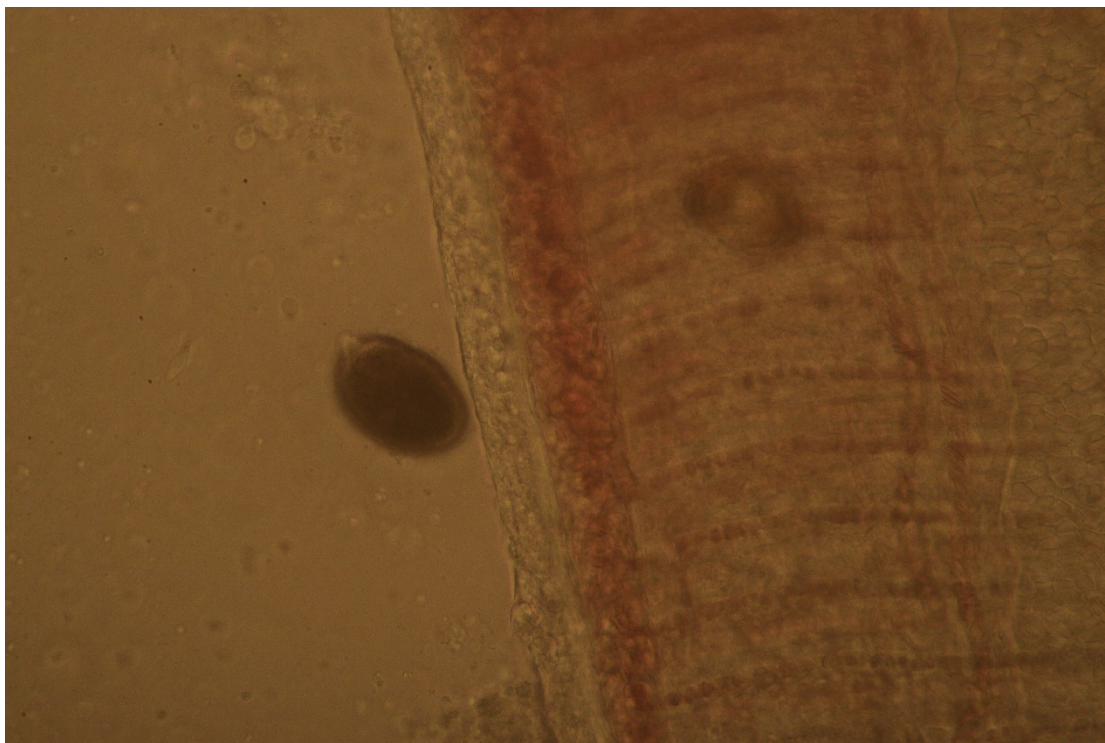


Figure 8 Amyloidium (Light microscopy x 400)

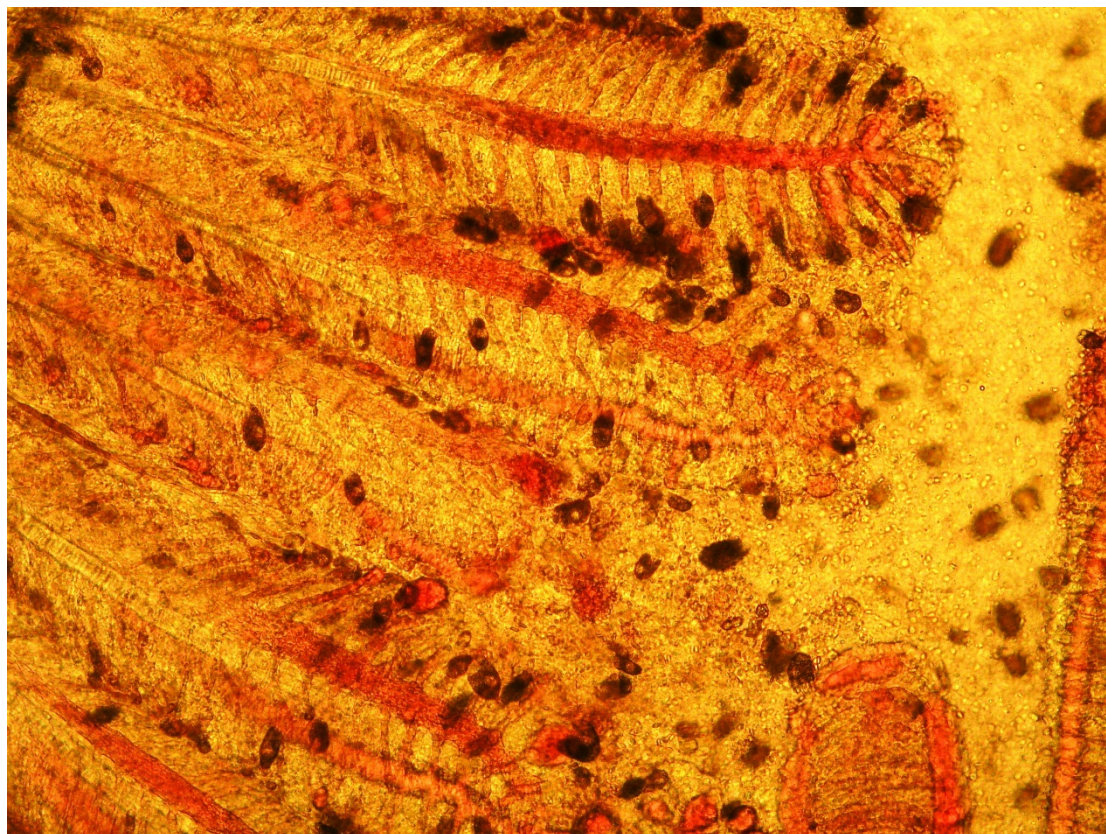


Figure 8a *Amyloodinium ocellatum* (phylum *s*) in the gills. Light microscopy x 100

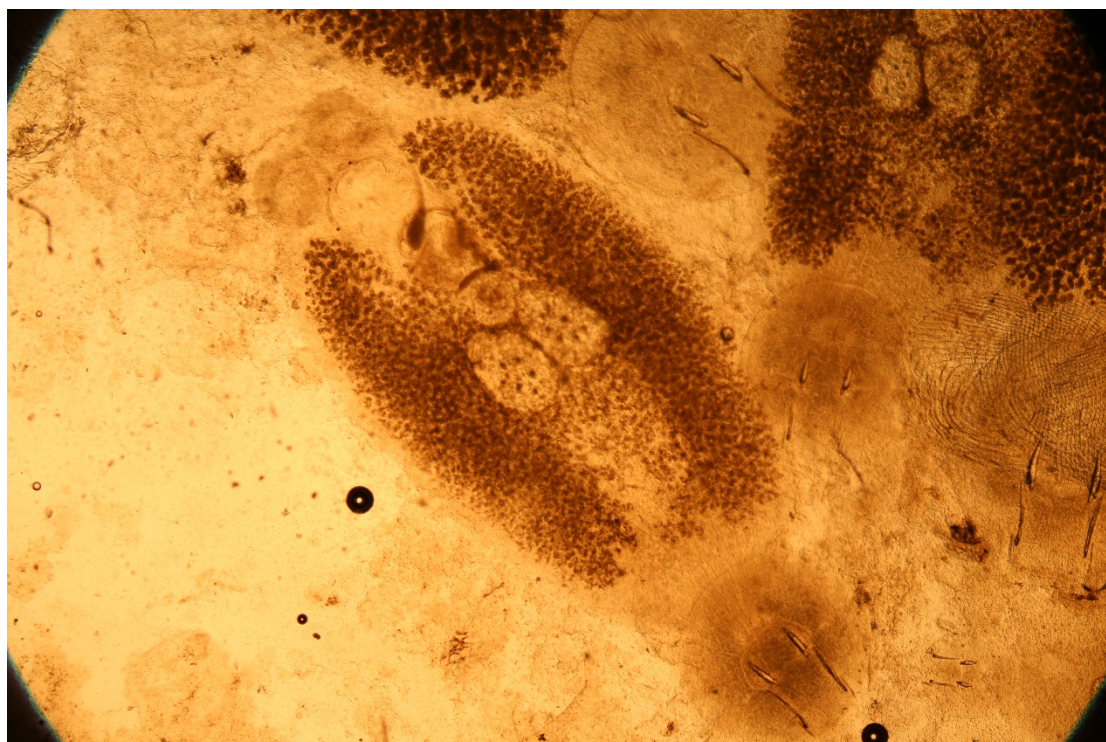


Figure 9 *Neobinidenia girellae* (light microscopy x 100)

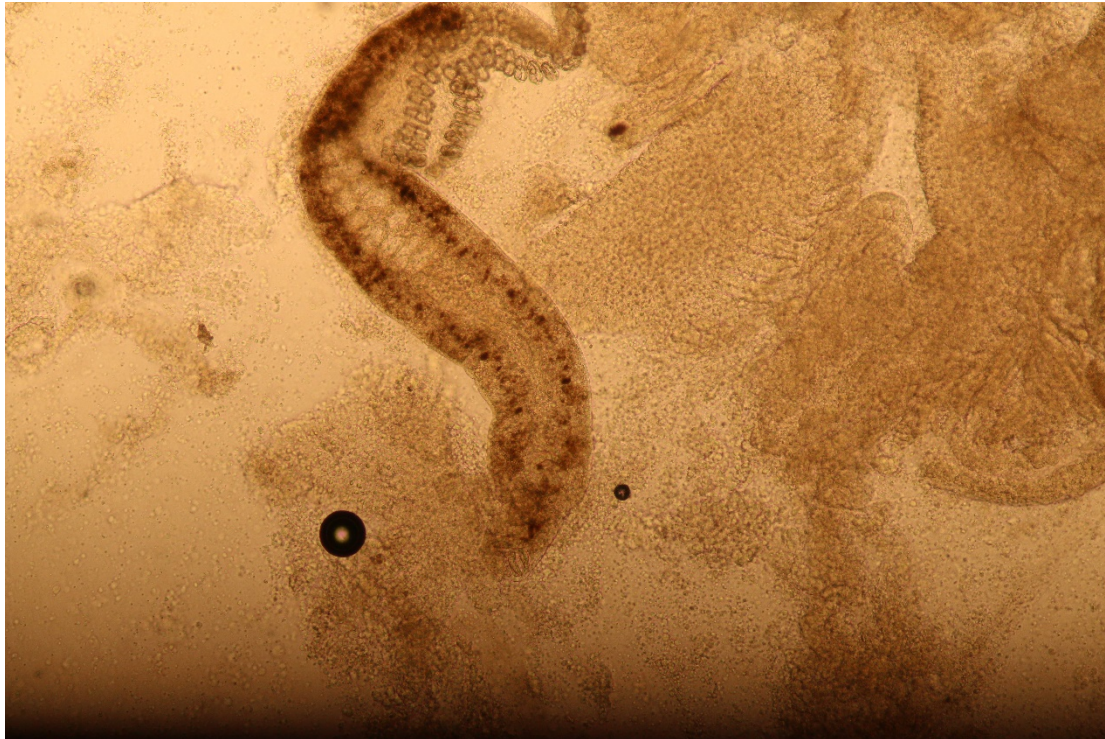

Figure 9a *Sparicotyle chrysophrii* x100

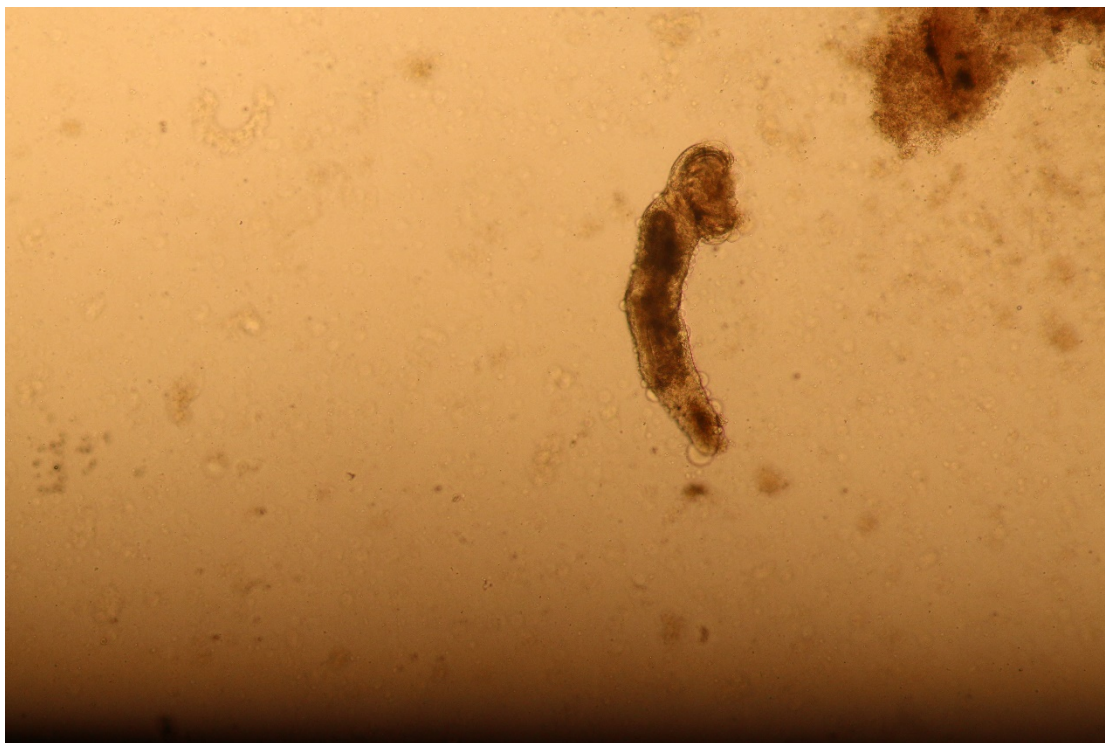


Figure 9b *Furnestinia echeneis* x100

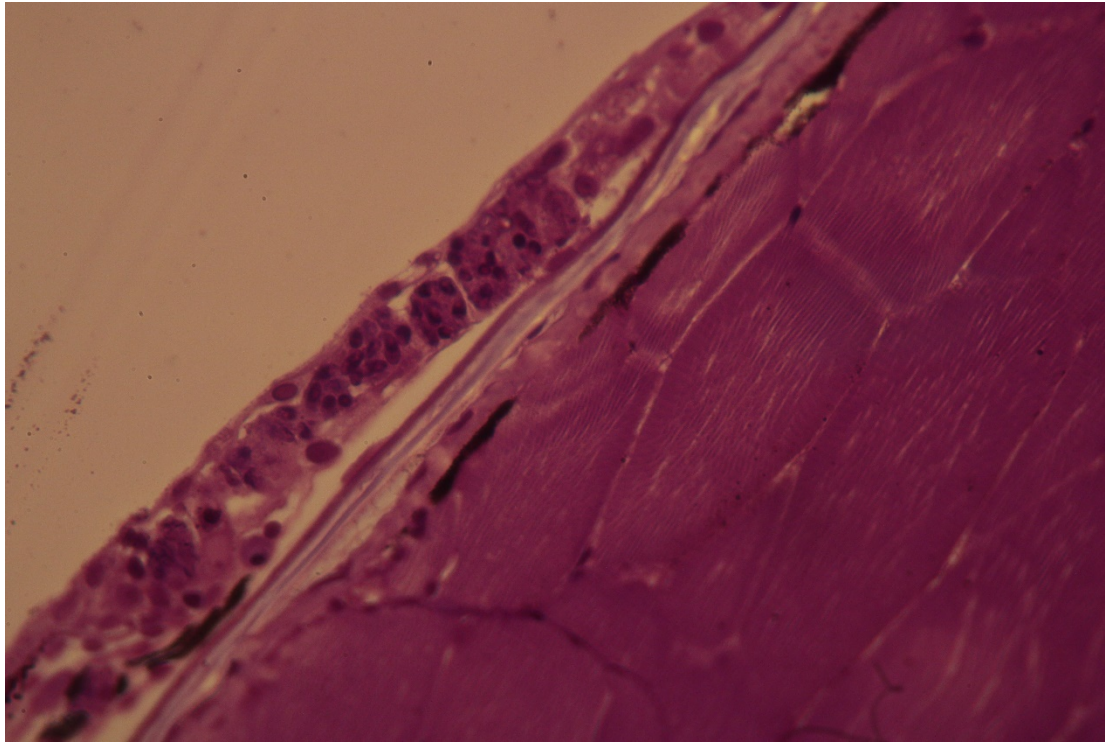


Figure 10 Microsporidian infection in the fish skin and muscle. Histology, Giemsa, x 1000

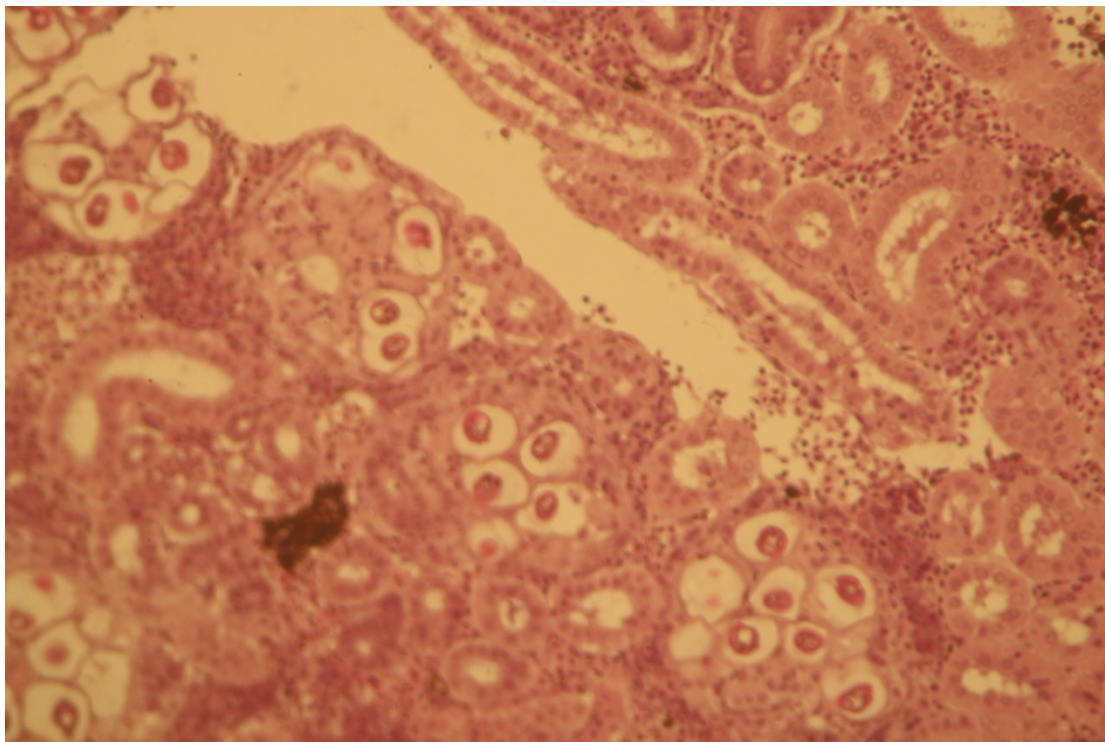


Figure 11 *Polysporoplasma sparis* in the kidney of sea bream (*Sparus aurata*) (H&E x 100)

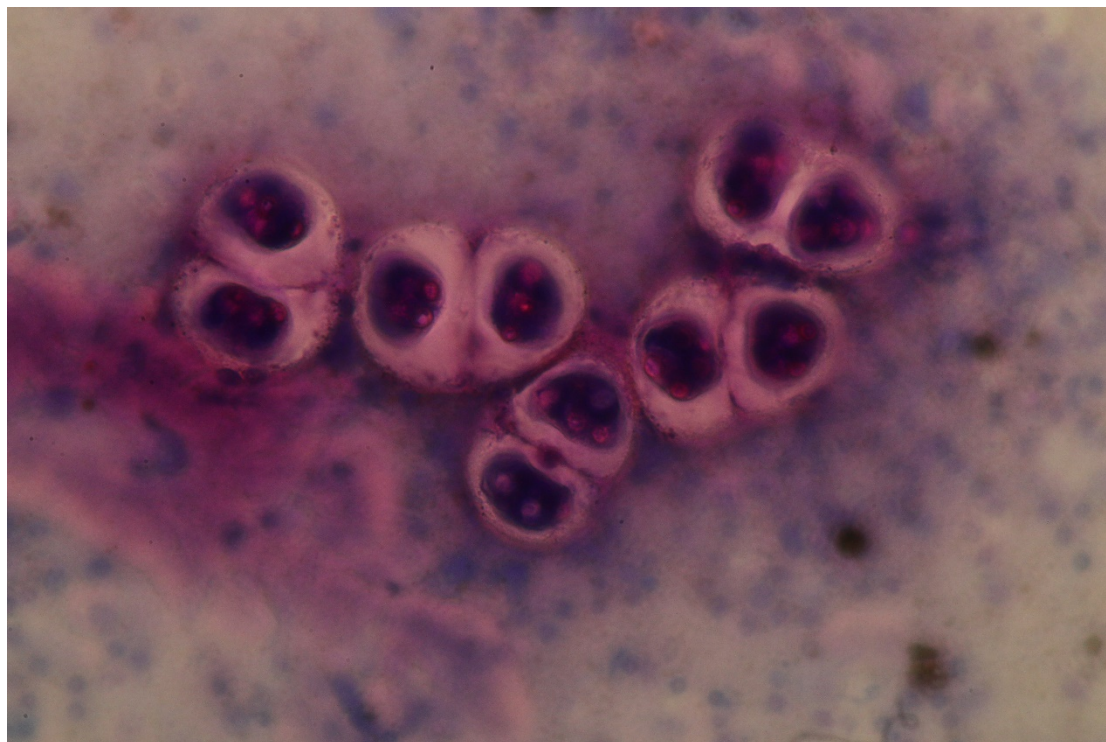


Figure 11a *Polysporoplasma sparis* in the kidney of sea bream (*Sparus aurata*) (cytology)

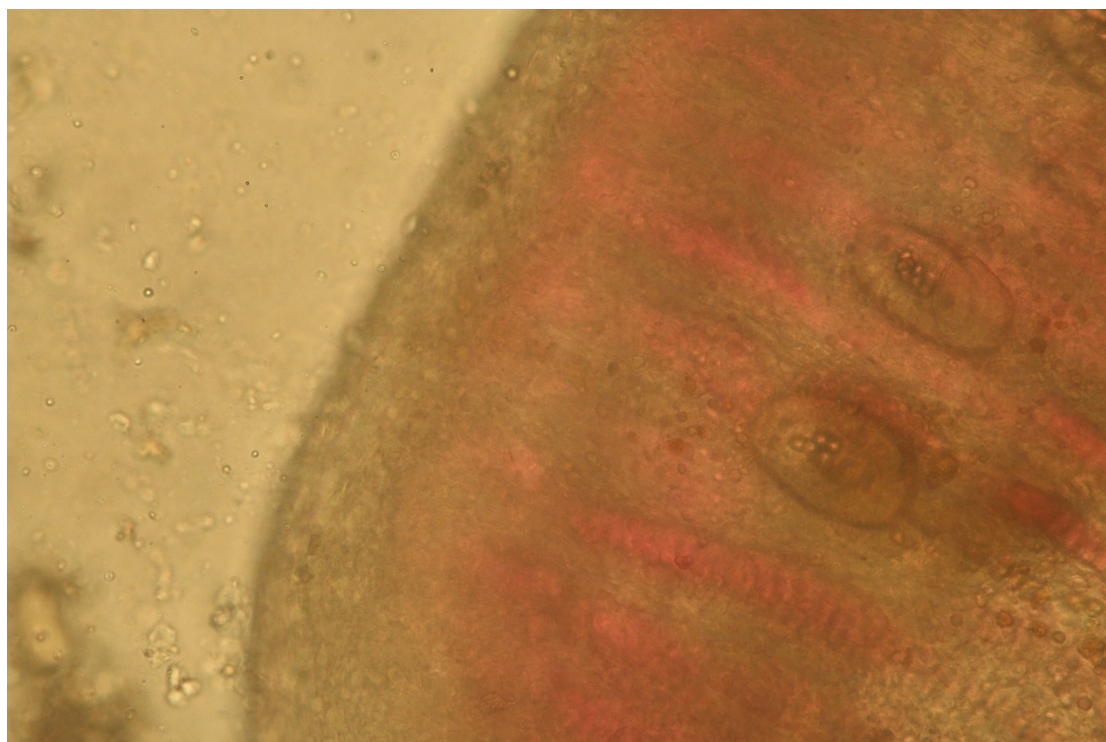


Figure 12 Digenean eggs in the vessels of gill filaments of *Epinephelus* x 400.

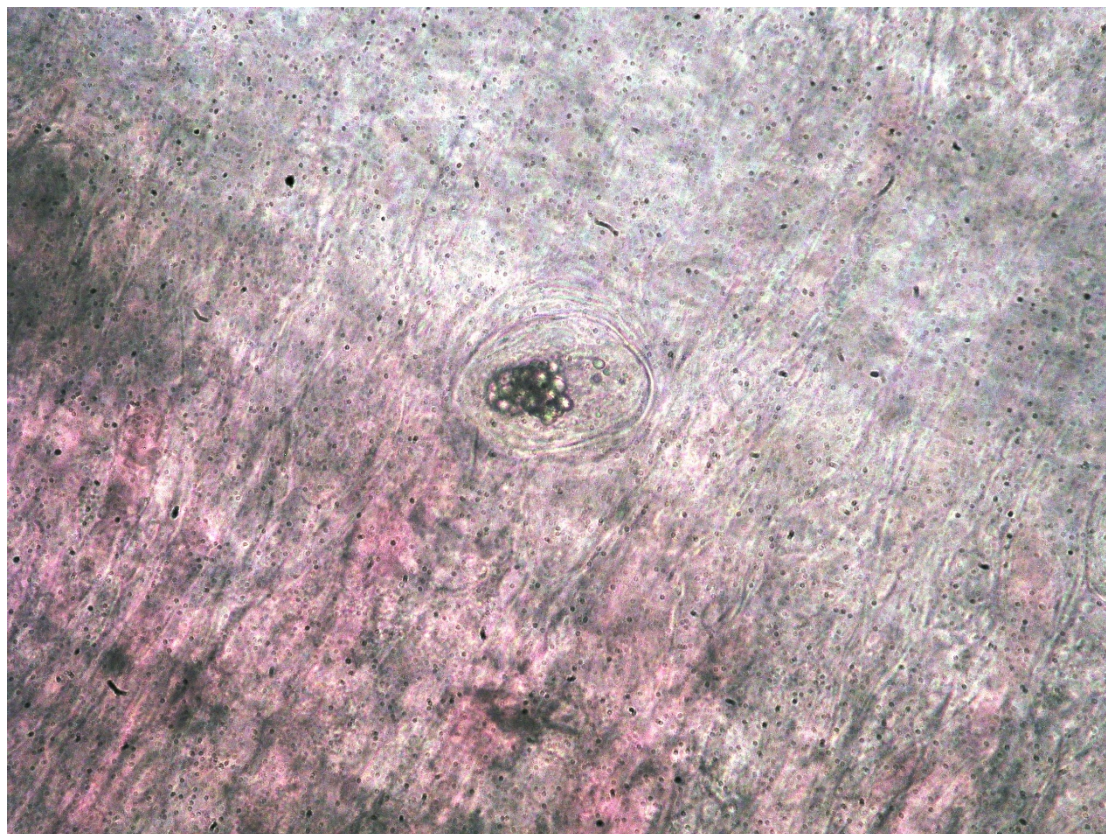


Figure 12a Seenguinilid egg in the gills x400

Discussion

The present survey is based on reports and updated data on fish pathogens in Israeli Mediterranean fish farms that were examined by CFHL from 2006 to 2021. There have been attempts to determine various pathogens' infection levels and find the significant fish health problems in cultured conditions.

Significant annual differences were found in the appearance of various agents during 15 –years. For a long period from 2006 to 2013, the main pathogens in the were VNN, *Photobacterium damsela* ssp. *piscicida*, *Mycobacterium* spp. Major monogenean parasites were *Diplectanum aequans*, *Furnestinia echeneis* (Paparna,1984), and *Sparicotyle chrysophrii*. Sometimes outbreaks caused by *Enteromyxum leei* were observed. Since 2013, our data showed apparent changes in the pathogen composition in cultured marine fish. VNN virus almost disappeared in fish of cage period and was detected only in the hatchery.

The discovery of *Megacytovirus (Iridovirus)* in November-December 2021 was an unpleasant surprise for Israeli marine culture that caused significant damage in its production (Smirnov et al., 2021).

Photobacterium damsela ssp. *piscicida* was not diagnosed for an extended period, but a few last years, it alone or in mixed infections with different *Vibrio* bacteria has been found. Co-infections of these two pathogens and parasites were detected in numerous outbreaks in sea farms. *Mycobacterium* spp. are rarely discovered as a cause of mortalities in the cultured cage fish, and *Streptococcus iniae* has not been noticed for several years.

The members of the bacterial genus *Vibrio* are often involved in fish outbreaks during the past five years. However, as mentioned above, they were primarily found in mixed infections. A new species, *V. ponticus*, was isolated several times from cultured fish without the presence of any other pathogen and was associated with mortalities. *Enteromyxum leei* are rarely observed in cage fish, but *Polysporoplasma spar* is often discovered during the last three years. It has a vast impact on fish health status. According to our data from

field investigations, this parasite weakens the fish and decreases the fish's ability to live, grow and survive. It causes chronic mortalities that may persist for weeks (CHFL data).

The monogenean parasites are one of the main problems in Israeli mariculture. We found that *Diplectanum aeguans* disappeared almost entirely from cage fish. *Sparicotyle chrysophrii* and *Furnestinia echeneis* stay on the same level, and *Neobenedenia girellae* and *Neobenedenia melleni* become frequently discovered parasites. It is found on the body and gills of cultured fish, causes severe damage, and proposes the fish to different additional infections followed by high mortalities.

Epitheliocystis became a serious increasing problem in Israeli mariculture in juveniles of marine fish, and their morbidity can be as high as 95%. The significance of such pathogens as *Enteromyxum leei*, *Mycobacterium sp.*, and *Diplectanum aeguans* became neglectable in Israeli cage farming.

New finding

During the last two years, per our findings, we have seen a significant increase of new pathogens in the mariculture industry along the Israeli coastline of the Mediterranean Sea such as *Megacytovirus*, *Neobenedenia*, *Microsporidia*-like agent, and *Vibrio ponticus* causing diseases in cultured fish that need further investigation.

Monitoring the health status of wild marine fish has the potential importance for understanding possible threats to fish farming. However, the findings of such surveys that were carried out by Meron et al. (2020) and Berzak et al. (2019) are significantly different from the actual situation of the fish health status on the marine cage farms and are irrelevant for the evaluation and prognosis of future pathological problems in Israeli mariculture.

The CFHL conducts surveys, such as this one, to improve farmers' ability to maintain fish health and steady production. The CFHL fish health survey provides updated information on the presence or absence of commercial finfish pathogens to the aquaculture industry, state of Israel officials, fisheries managers, conservation NGOs, academia researchers, and the public. This information helps to better manage both hatchery and offshore caged fish populations. Hopefully, our survey can assist finfish producers along the Mediterranean Sea decide where and how to manage their fish farms and model for future pathogen occurrences.

References

- Abela M, Brinch-Iversen J, Tanti J**, 1996. Occurrence of a new histozoic microsporidian (Protozoa, Microspora) in cultured gilt head sea bream *Sparus aurata* L. *Bulletin of the European Association of Fish Pathologists*, 16, 196–199.
- Bartošová P, Fiala I, Jirku M, Cinková M, Caffara M, Fioravanti ML, Atkinson SD, Bartholomew JL, Holzer AS, Sitja-Bobadilla A, Alvarez-Pellitero P**, 1995. Sphaerospora sensu stricto: taxonomy, diversity and evolution of a unique lineage of myxosperans (Myxozoa). *Mol Phylogenetic Evol* 68:93–105. <https://doi.org/10.1016/j.ympev.2013.02.026>
- Beraldo P, De Nigris G, Rogato F, Galeotti M**, 2007. Histological and immunohistochemistry findings of viral encephalopathyretinopathy in gilthead sea bream larvae (*Sparus aurata*, L. 1578) reared in Italy. *Eur Assoc Fish Pathol*, 13th Int Conf Fish Shellfish Dis. Grado, Italy. 140.
- Berzak R, Scheinin A, Davidovich N, Regev Y, Diga R, Tchernov D, Danny Morick D**, 2019. Prevalence of nervous necrosis virus (NNV) and Streptococcus species in wild marine fish and crustaceans from the Levantine Basin, Mediterranean Sea. *Dis Aquat Org*. Vol. 133: 7–17 <https://doi.org/10.3354/dao03339>
- Colorni A**, 1992. A systemic mycobacteriosis in The European sea bass *Dcentrarchus labrax* cultured in Eilat (Red Sea). *Israeli Journal of Aquaculture - Bamidgeh* 44(3) 75–81
- Colorni A, Diamant A**, 1995. Splenic and cardiac lymphocystis in the red drum, *Sciaenops ocellatus* (L.). *Journal of Fish Diseases* (United Kingdom). (1), 38–45. <https://doi.org/10.1111/j.1365-2761.1995.tb00339.x>
- Colorni A, Paperna I, Gordin H**, 1981. Bacterial infections in gilthead sea bream *Sparus aurata* cultured at Elat. *Aquaculture*. 23: 257– 267.

- Diamant A, Lom J, Dykova I**, 1994. Myxidium leei n. sp., a pathogenic myxosporean of cultured sea bream *Sparus aurata*. *Dis Aquat Org.* 20: 137-141.
- Egusa S**, 1987. Epitheliocystis disease, a review. *Fish Pathology*, **22**, 165-172.
- Gordin H**, 2003. Mariculture in Israel. *Israeli Journal of Aquaculture – Bamidgeh*, 55. <https://doi.org/10.46989/001c.20359>
- Holzer AS, Montero FE, Repulles-Albelda A, Raga JA**, 2007. Morphological characterization and phylogenetic positioning of a new sanguinicolid blood fluke, a pathogen in Mediterranean *Sparus aurata* L. culture. *Eur Assoc Fish Pathol*, 13th Int Conf Fish Shellfish Dis. Grado, Italy. 179.
- Kurita J, Nakajima K**, 2012. Megalocytiviruses. *Viruses*, 4(4), 521-538. <https://doi.org/10.3390/v4040521>
- Macián MC, Garay E, Grimont PA, Pujalte MJ**, 2004. *Vibrio ponticus* sp. nov., a neighbour of *V. fluvialis*-*V. furnissii* clade, isolated from gilthead sea bream, mussels and seawater. *Systematic and applied microbiology*. 1;27(5):535-40.
- Meron D, Ofek-Lalzar R, Berzak A, Scheinin Y, Regev, Diga R, Tchernov D, Morick D**, 2020. Specific pathogens and microbial abundance within liver and kidney tissues of wild marine fish from the Eastern Mediterranean Sea. *Microbial Biotechnology* 13(3) 770-780.
- Nitzan S, Shwartsburd B, Vaiman R, Heller ED**, 2001. Some characteristics of *Photobacterium damsela* ssp. *piscicida* isolated in Israel during outbreaks of pasteurellosis in hybrid bass (*Morone saxatilis* x *M. chrysops*). *Bulletin of the European Association of Fish pathologists* 21(2) 77-81.
- Paperna I**, 1977. Epitheliocystis infections in wild and cultured sea bream (*Sparus aurata*, Sparidae) and grey mullets (*Liza ramada*, Mugilidae). *Aquaculture*. 10: 169-176. *et des Sparid'és* (eds. G. Barnabé & R. Billard), pp. 465-482. *INRA Publishing*, Paris.
- Paperna I**, 1981. "Parasites and Diseases of Mullet (Mugilidae)" *Faculty Publications from the Harold W. Manter Laboratory of Parasitology*. 579. <http://digitalcommons.unl.edu/parasitologyfacpubs/579>
- Paperna I**, 1984. Review of diseases affecting cultured *Sparus aurata* and *Dicentrarchus labrax* [sea bream, sea bass; Dinoflagellate, trichodines, bacterial diseases, metabolic disorders mainly]. In *L'aquaculture du bar (loup) et des Sparides, Sete (France), 15-17 Mar 1983*. INRA.
- Paperna I**, 1991. Diseases caused by parasites in the aquaculture of warm water fish. *Ann Rev Fish Dis*.1: 155-194.
- Shilo M, Sarig S**, 1989 *Fish culture in warm water systems: Problems and Trends* CRC PRESS 4-13.
- Sitja-Bobadilla A, Alvarez-Pellitero P**, 1995. Light and electron microscopic description of *Polysporoplasma* n.g. (Myxosporidia: Bivalvulida), *Polysporoplasma sparidis* n.sp from *Sparus aurata* (L), and *Polysporoplasma mugilis* n. sp. from *Liza aurata* L. *Eur. J. Parasitol.* 31: 77-89.
- Ucko M, Colorni A, Kvitt H, Diamant A, Zlotkin A, Knibb WR**, 2002. Strain variation in *Mycobacterium marinum* fish isolates. *Applied Environmental Microbiol.* 68(11): 5281-5287. <https://doi.org/10.1128/AEM.68.11.5281-5287.2002>
- Ucko M, Colorni A, and A Diamant**, 2004. Nodavirus infections in Israeli mariculture. *Journal of Fish Diseases*, 27, 459-469. <https://doi.org/10.1111/j.1365-2761.2004.00565.x>
- Vendramin N, Zrncic, S, Padrós F, Oraic D, Le Breton A, Zarza C, and Olesen NJ**, 2016. Fish health in Mediterranean Aquaculture, past mistakes, and future challenges. *Bull. Eur. Ass. Fish Pathol.*, 36(1)