



Case of the Month

Surgical extirpation of a chest wall desmoid tumor: A Case Report

Niten Singh, MD and Jeffrey P. Kavolius MD
Department of Surgery
Tripler Army Medical Center
Honolulu, Hawaii

Abstract

A case is described of an anterior chest wall desmoid tumor in a 20-year-old Micronesian male that had been previously incompletely resected one year prior to presentation. A radical chest wall resection was performed with reconstruction accomplished using a gortex patch and latissimus dorsi myocutaneous flap. The patient developed a massive local recurrence within eight months following surgery. This report illustrates the local aggressiveness of these benign tumors. A historical perspective, etiology, and treatment principles are discussed.

Case Report

A 20-year-old Kosraen male was referred for treatment of a recurrent left anterior chest wall desmoid. Approximately one year prior to referral the patient underwent an excisional biopsy. The mass quickly returned and, in fact, doubled in size over the preceding four months prior to referral. The patient did not describe any functional disability related to the mass, and was otherwise healthy except for a seizure disorder.

Physical examination revealed a 12cm x 18cm mass of the left anterior chest wall, extending from above the clavicle superiorly to the axilla laterally (Figure 1). The neurovascular examination of the left upper extremity was normal. Chest x-ray and CT scan showed the mass arising from the chest wall with a prominent intrathoracic component. The mass was intimately associated with the brachial plexus and subclavian artery and vein (Figure 2).

The patient underwent a radical chest wall resection to include the clavicle, the first and second ribs, a portion of the manubrium, and the pectoralis major and minor muscles. Complete tumor clearance was obtained. There was obviously little if any margin along the brachial plexus, artery, and vein. Reconstruction was accomplished using a gortex patch and a latissimus dorsi myocutaneous rotation flap (Figure 3). The patient's post-operative course was unremarkable. External beam radiotherapy was recommended to aid in local control, however, the patient declined opting instead to return home to Kosrae. Eight months later, he was noted to have a massive recurrence involving the entire shoulder girdle, which extended intrathoracically (Figure 4). Since the patient declined further surgery it was recommended that he be placed on tamoxifen.

Discussion

The term desmoid arises from the Greek word *desmos* meaning bandlike.¹ The first description of desmoid tumors in the literature was from McFarlane in 1832 who described two cases of abdominal wall desmoid tumors. In 1849 Bennet described the microscopic characteristics of 3 growths occurring on the thigh, parotid region, and in the arm, respectively. These tumors all recurred after local

excision. Paget in 1856 also reported on two cases of desmoid tumors in the abdominal wall and forearm, and under the microscope noted that these tumors were of the same origin. He suggested trauma as an etiologic factor.²

Figure 1

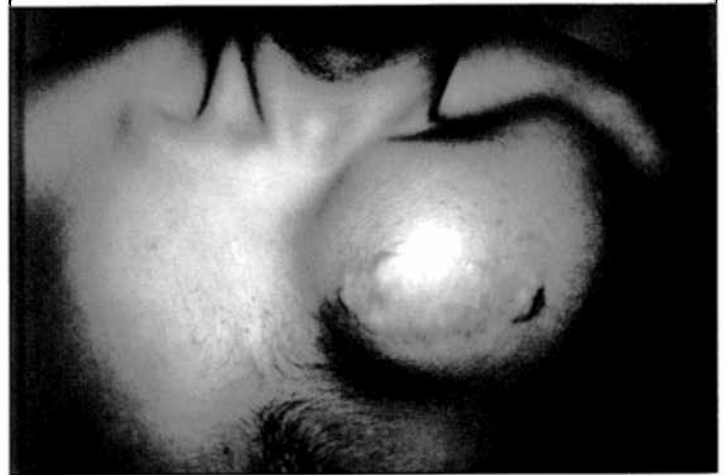

Figure 2

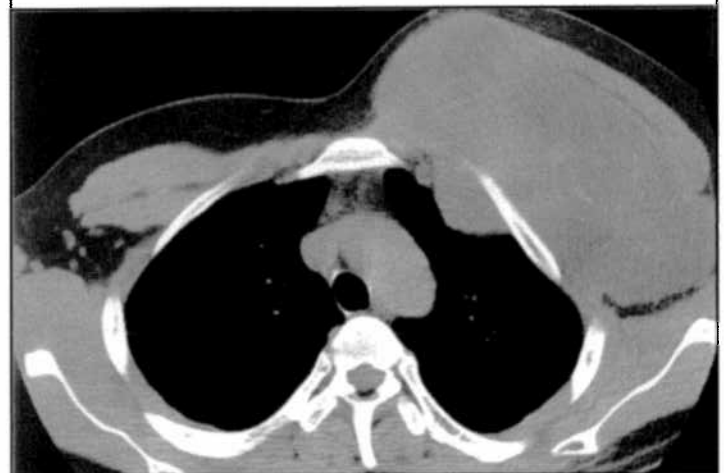

Figure 3

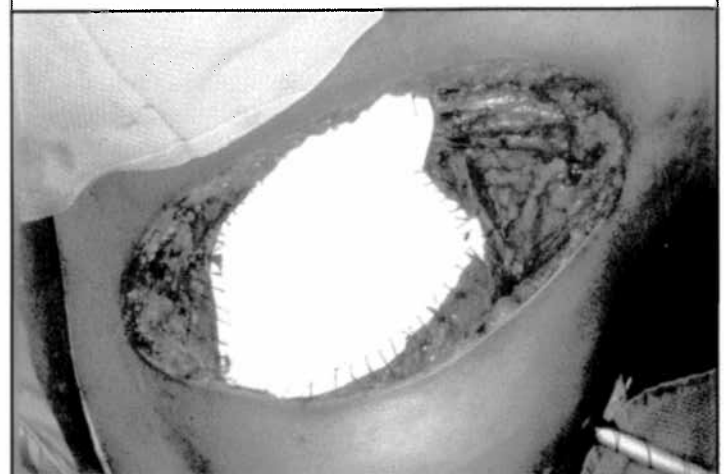
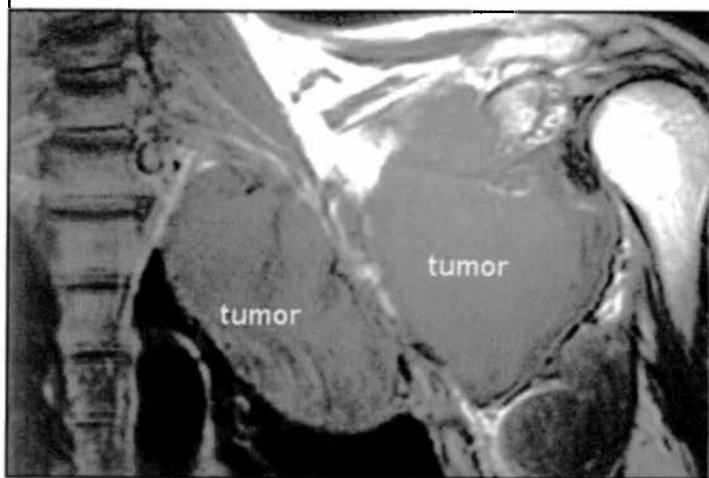


Figure 4



Desmoid tumors are histologically benign neoplasms that are poorly encapsulated and are characterized by a locally infiltrative growth pattern. It is this behavior that is responsible for high rates of local recurrence despite wide resection. The natural history of these tumors is that of slow, locally invasive growth that may stop or even regress.³ Desmoid tumors have the potential for malignant transformation and, in fact, may be difficult to distinguish from low-grade fibrosarcomas. Desmoids may occur sporadically or may be seen in association with familial polyposis coli syndrome (FAP), suggesting a hereditary predisposition. Sporadic forms occur primarily within the abdominal wall and extraabdominal sites whereas desmoids associated with FAP occur primarily within the bowel mesen-

tery.⁴ Pregnancy, estrogenic hormones, and trauma have all been implicated in the etiology of these unusual and unpredictable tumors.⁵ The overall incidence of desmoids is approximately 2-4 cases per million population per year with a predilection for females. They represent 0.03% to 0.1% of solid tumors and occur in the following distribution: 58% extraabdominal; 36% within the abdominal wall; and 15% intraabdominally.¹ Chest wall desmoids account for approximately 20% of all desmoid tumors.

Surgery is the mainstay of therapy for these neoplasms. The goal of surgical therapy is to achieve a negative pathologic margin. What remains controversial, however, is how radical surgery should be to achieve this goal. A positive or close margin following resection would intuitively predict for local recurrence. This, however, has not been consistently shown in the collected series.^{6,7,8} It is generally accepted, therefore, that aggressive attempts at achieving negative pathologic margins that result in severe disfigurement, limb loss, or neurologic impairment is not justified. As noted by Lewis *et al.* (6), function and structure preserving procedures should be goals of therapy. The use of radiation therapy in the setting of close or positive margins may improve local control, although this is subject to debate as well.⁹⁻¹² Because desmoids appear to be hormonally mediated tumors as evidenced by their common presentation during pregnancy as well as reports documenting regression after menopause and after oophorectomy, hormonal agents such as tamoxifen have been used for treatment.^{7,13} Nonsteroidal anti-inflammatory agents have also been used. Treatment with these agents is typically in the setting of close margins following resection or for recurrent disease. Response rates are on the order of 50% with these agents.¹⁴ Overall survival and disease-free survival at 20 years for desmoid tumors are approximately 90% and 65-70%, respectively.^{4,5}

References

1. Pereyo, NG and Heimer, WL. Extra-abdominal desmoid tumor. *Journal of American Academy of Dermatology*. 34: 352-356. 1996.
2. Hayry, P. and Scheinin, TM. The Desmoid (Reitamo) Syndrome: Etiology, manifestation, pathogenesis, and treatment. *Current Problems in Surgery*. 24: 1988. 233-320.
3. Mendez-Fernandez, MA and Gard, DA. The desmoid tumor: "benign" neoplasm, not a benign disease. *Plast.Reconstr.Surg.* 87:956-960. 1990.
4. Lynch, HT, Fitzgibbons, R. Surgery, Desmoid Tumor and Familial Adenomatous Polyposis: Case Report and Literature Review. *American Journal of Gastroenterology*. 91:2598-2601. 1996
5. Moley, JF and Eberlein, TJ. Soft tissue Sarcomas. *Surgical Clinics of North America*. 80: pp. 2000.
6. Lewis, JJ, Boland, PJ, Leung, DHY, Woodruff, JM and Brennan, MF. The Enigma of Desmoid of Tumors. *Annals Surgery* 229: 866-873. 1999.
7. Easter, DW and Helasz, NA. Recent trends in the management of desmoid tumors. Summary of 19 cases and review of the literature. *Annals of Surgery*. 210: 765-769. 1989.
8. Mirabell, R., Suit, HD., Mankin, HJ. *et al.* Fibromatoses: from postsurgical surveillance to combined surgery and radiation therapy. *Int J Radiat Oncol Biol Phys* 1990; 18: 535-540.
9. Ballo, MT, Zagars, GN, Pollack, A *et al.* Desmoid Tumors: prognostic factors and outcome after surgery, radiation therapy or combined surgery and radiation therapy. *J.Clin.Oncol.* 17: 158-166. 1999.
10. Brooks, JS. Concepts in the pathology of soft tissues: A primer for General Surgeons. In *Problems in General Surgery: Soft tissue tumors*. William G. Kraybill ed. 16:13-23. 1999.
11. Reitamo, JJ. The desmoid tumor: choice of treatment, results and complications. *Archives of Surgery*. 118:1318-1322. 1983.
12. Kiel, KD and Suit, HD. Radiation therapy in treatment of aggressive fibromatoses (Desmoid tumor). *Cancer*. 54:2051-2055. 1984.
13. Reitamo, JJ, Schein, TM, Hayry, P. The desmoid syndrome. New aspects in the cause, pathogenesis, and treatment of the desmoid tumor. *American Journal of Surgery*. 152: 230-237. 1986.
14. Waddell, WR, Kirsch, WM. Testolactone, sulindac, warfarin, and vitamin K1 for unresectable desmoid tumors. *American Journal of Surgery*. 161: 416-421. 1991.

ARRIVAL NOTICE



Steinway Pianos

Great New Selection Of Steinway Grands & Uprights! Including Rare Exotic Woods, Designer Styles and Limited Editions.

- Largest Piano Inventory In Hawaii ~ New & Used
- Guaranteed Lowest Prices

Open 7 Days
A Week



1500 S. King Street
946~6500

Neighbor Islands Toll Free 1-800-704-0441