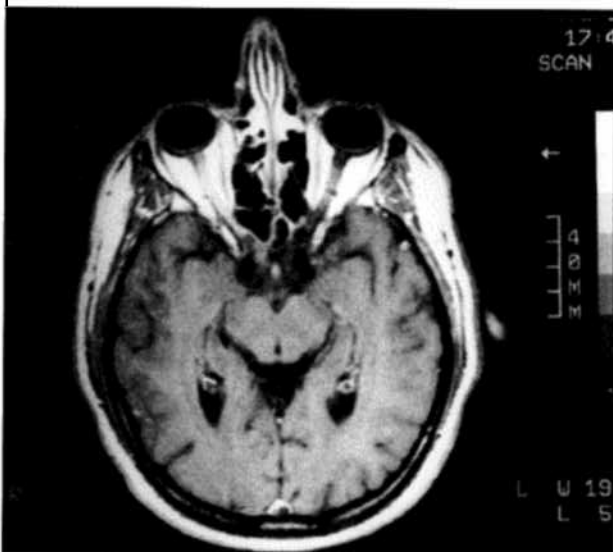


# Recent Advances in the Management of Optic Neuritis

Scott Kortvelesy MD

Optic neuritis is an acute demyelinating disease of the optic nerve. The typical patient reports a unilateral reduction in vision progressing over several days, commonly associated with pain on eye movement. The visual acuity usually "bottoms out" at 7-14 days and then slowly recovers over 6-12 weeks. Permanent reduction of visual acuity and even blindness may occur. Diagnosis is based on the patient history, reduced visual acuity, color vision and visual field, as well as the presence of an afferent pupillary defect (Marcus-Gunn pupil). Disc swelling is variable. Although MRI may visualize a signal abnormality along the optic nerve (see Fig. 1), it is usually not necessary to make the diagnosis.

Fig. 1.—Axial T1-weighted MRI scan showing signal enhancement of entire length of right optic nerve.



While it may be an isolated event, optic neuritis takes much larger significance from its association with multiple sclerosis. Long term studies have shown that 15 years after an attack of optic neuritis, 34% of men and 74% of women will develop multiple sclerosis.<sup>1</sup>

The Optic Neuritis Treatment Trial is a national collaborative study funded by the National Eye Institute of Bethesda, Maryland. It is a randomized, placebo controlled trial of 457 patients to look at the natural history of no treatment versus steroid treatment of optic neuritis.<sup>2</sup>

The mean age of patients recruited for the study was 32 years, and 77% were women.<sup>3</sup> The optic nerve was ophthalmoscopically normal in 65% and edematous in 35%. The visual loss was associated with pain in 92% of cases. Magnetic resonance imaging

showed changes "consistent with" demyelinating disease in 49% of patients. As expected, nearly all of the patients (98%) had visual field defects in the affected eye, but the "unaffected" fellow eye had a surprisingly high rate of abnormal visual fields at 48%.

The optic neuritis treatment trial randomized patients with acute optic neuritis to one of three groups: 1) Prednisone 1 mg/kg/day for 14 days, 2) Intravenous methylprednisolone 1 gm/day for 3 days followed by 11 days of oral prednisone at 1 mg/kg/day, or 3) oral placebo for 14 days. Patients were then followed for changes in visual acuity, color vision, visual field and contrast sensitivity.

The study concluded that while treatment with intravenous methylprednisolone hastened the visual recovery, there was no long-term visual benefit over placebo. Surprisingly, the study also found that those patients treated with oral prednisone alone had an increased risk of recurrent optic neuritis. Therefore, treatment of the demyelinating form of optic neuritis with prednisone alone is not recommended.

Two year follow-up data indicated that those patients with signal abnormalities on brain MRI had a much higher risk for the development of definite multiple sclerosis.<sup>4</sup> By three years, the risk for definite MS was 43% for those who had three or more lesions on the baseline brain MRI.<sup>5</sup> This compared with a 28% risk among those with one or two signal abnormalities and only a 9% risk in those with normal scans or scans with nonspecific changes at baseline. The two year data also strongly suggested that intravenous methylprednisolone reduced the rate of development of multiple sclerosis compared with placebo (7.5% versus 16.7%). Unfortunately this protective effect of methylprednisolone is temporary. Preliminary four year follow-up data showed that clinically definite multiple sclerosis developed in 25% of those treated with intravenous methylprednisolone versus 27% of those treated with placebo.

Based on these results and in view of the availability of new medications such as Betaseron and Avonex for treatment of multiple sclerosis, it seems reasonable to recommend an MRI scan of the brain on any new patient with acute optic neuritis. If the MRI shows evidence of demyelinating disease or if the patient needs or desires a quicker recovery of vision, then intravenous methylprednisolone should be offered.

## References

1. Rizzo, JF, Lessell, S: Risk of developing multiple sclerosis after uncomplicated optic neuritis. *Neurology* 1988; 38: 185-190.
2. Beck, RW, Cleary PA, Anderson MM, et al: A randomized, controlled trial of corticosteroids in the treatment of acute optic neuritis. *N Engl J Med* 1992; 326: 581-588.
3. Optic Neuritis Study Group: The clinical profile of optic neuritis. *Arch Ophthalmol* 1991; 109: 1673-1678.
4. Beck, RW, Cleary, PA, Trobe JD, et al: The effect of corticosteroids for acute optic neuritis on the subsequent development of multiple sclerosis. *N Engl J Med* 1993; 329: 1764-1769.
5. Beck, RW: The optic neuritis treatment trial: Three year follow-up results. *Arch Ophthalmol* 1995; 113: 136-137.