
Advances in Ophthalmic Plastic, Reconstructive and Orbital Surgery in Hawaii

Jorge G. Camara MD*

Advances in ophthalmic plastic and reconstructive surgery continue to be made in the state of Hawaii. A new technique of dacryocystorhinostomy using the endoscope and the pulsed Holmium: YAG laser as well as a subconjunctival endoscopic assisted approach to orbital surgery for orbital decompression is described. The integrated hydroxyapatite implant replacing the enucleated eye gives excellent postoperative extraocular motility.

History of Ophthalmic Plastic and Reconstructive Surgery

Ophthalmic plastic surgery is any surgery that changes the form of the adnexal tissues of the eye (from the Greek *ophthalmos*, meaning eye, and *plastos*, meaning formed). Thus, ophthalmic plastic surgery includes repair of eyelid malpositions, eyelid and orbital reconstruction, conjunctivoplasty, cosmetic blepharoplasty, lacrimal surgery, orbitotomy procedures, and the treatment of orbital socket deformities.¹

Examples of ocular diseases treated by ophthalmic plastic and reconstructive surgeons are ptosis, eyelid malpositions such as entropion and ectropion, cancers of the eyelids and ocular surface, malignant exophthalmos, orbital tumors and blocked tear ducts.

Deformities of the orbital region from congenital defects, trauma, neoplasms, and/or infectious diseases have afflicted men throughout the ages. Prehistoric skeletal remains reveal deformities that did not cause death, but ocular disability. The oldest surviving reference to oculoplastic surgery is a passage from the Code of Hammurabi (2250 BC) that refers to treatment of an infected lacrimal sac:

"If a physician performs on a patient a deep cut with the operating knife or if he opens with a knife an (abscess of cavity) and the eye is lost, the physician's hands shall be cut off."

*Chairman, Dept. of Ophthalmology and Otolaryngology
St. Francis Medical Center
Clinical Assistant Professor
Division of Ophthalmology
University of Hawaii School of Medicine

Correspondence to author:
Jorge G. Camara MD
2228 Liliha Street, Suite 106
Honolulu, Hawaii 96817

References to the surgical repair of entropion go as far back as Hippocrates (460-380 BC); the first century Roman philosopher Celsus (25 BC to 50 BC) believed that reconstruction of mutilated eyelids was hopeless.²

The development of modern day ophthalmic plastic and reconstructive surgery was started by Byron Smith, an ophthalmologist, and John Converse, a plastic surgeon, who met during World War II. They collaborated in the repair of ocular and adnexal injuries sustained by American soldiers, and described the diagnosis and treatment of complex naso-orbital fractures.³ Subsequent work by Fox, Callahan, Hughes, and Beard contributed greatly to the development of this subspecialty.

Ophthalmic plastic and reconstructive surgery has evolved from these beginnings into a distinct discipline of ophthalmology. Fellowship training programs in ophthalmic plastic, lacrimal and orbital surgery ranging from one to two years are offered by most large training programs in the United States.

New techniques in laser lacrimal surgery for correcting nasolacrimal duct obstruction have been developed in Hawaii. Endoscopic assisted orbital surgery for removal of orbital tumors, repair of orbital fractures and orbital decompression for Graves' ophthalmopathy has been advanced in Hawaii. The first large long term study of the adjunctive use of Mitomycin C in endoscopic laser assisted dacryocystorhinostomy has been completed and submitted for publication.

Endoscopic Laser Assisted Dacryocystorhinostomy

Obstruction of the nasolacrimal drainage system may cause problems ranging from troublesome epiphora to chronic infection, and formation of a dacryopyocele with abscess formation. Because the medial angular veins drain into the cavernous sinus, these infections are considered to be a medical emergency requiring prompt treatment. (Fig. 1)

The time honored method of correcting a blocked tear duct is an external dacryocystorhinostomy which has an over 90% success rate.⁵ This operation, however, does have disadvantages such as the skin incision between the bridge of the nose and the medial boundary of the eyelid; the potential for significant intraoperative bleeding from the medial angular vessels and nasal mucosa; postoperative pain requiring pain-suppressants, and the need for approximately a week of recovery time.

The use of the endoscope, with the pulsed high-powered Hol-

Fig 1.—Three year old female child with untreated congenital nasolacrimal duct obstruction forming lacrimal sac abscess.

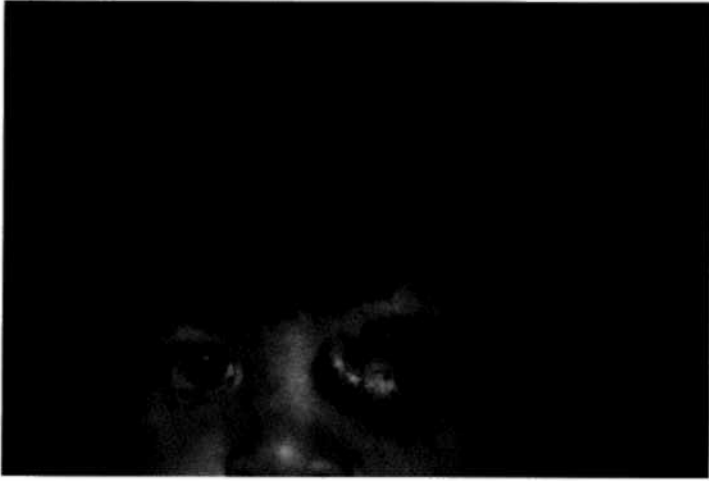

Fig 2.—Intraoperative intranasal photograph of osteotomy with silicone stents in place immediately after endoscopic laser assisted dacryocystorhinostomy.

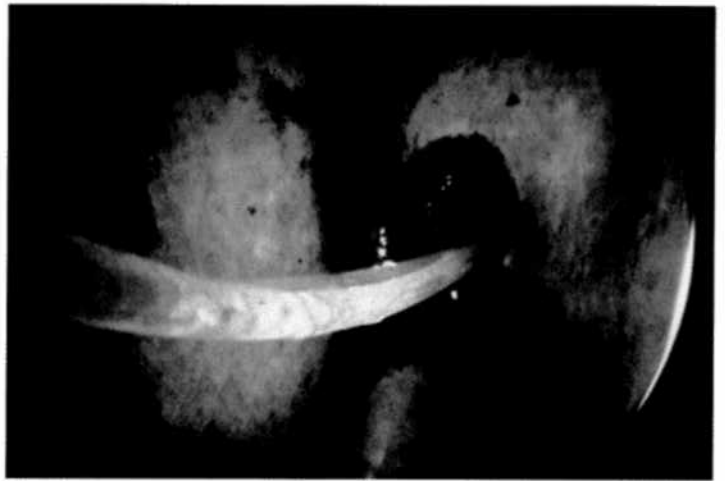

Fig 3.—Thirty six year old Hawaiian female with malignant exophthalmos and optic neuropathy causing severe visual loss in both eyes.

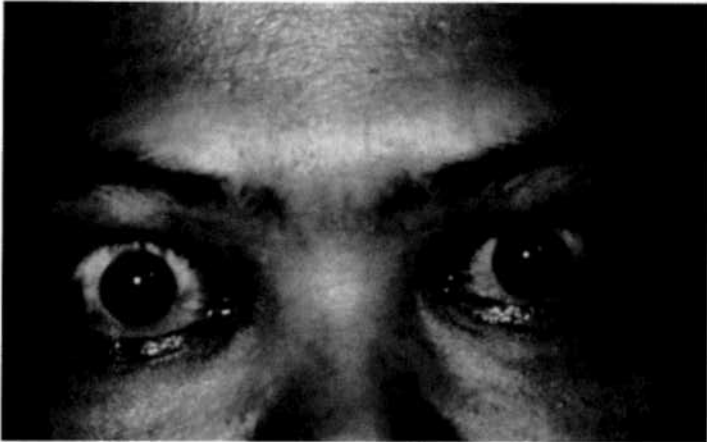

Fig 4.—Same patient after undergoing endoscopic assisted three wall orbital decompression to both eyes with recovery of visual acuity bilaterally.

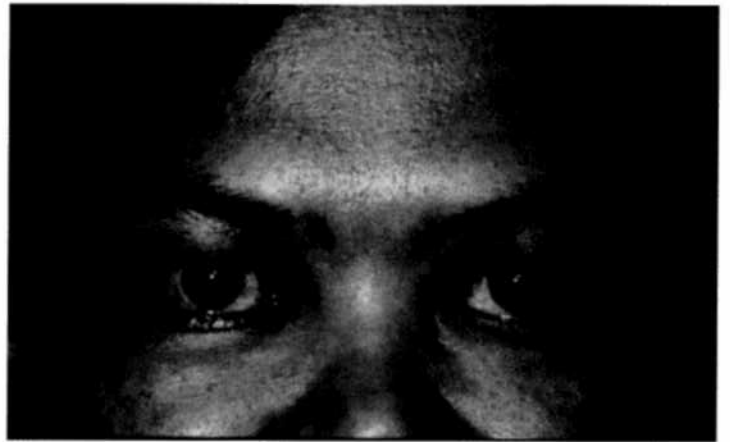

Fig 5.—Nine year old male status post enucleation of both eyes due to retinoblastoma with severe orbital atrophy and socket contracture.

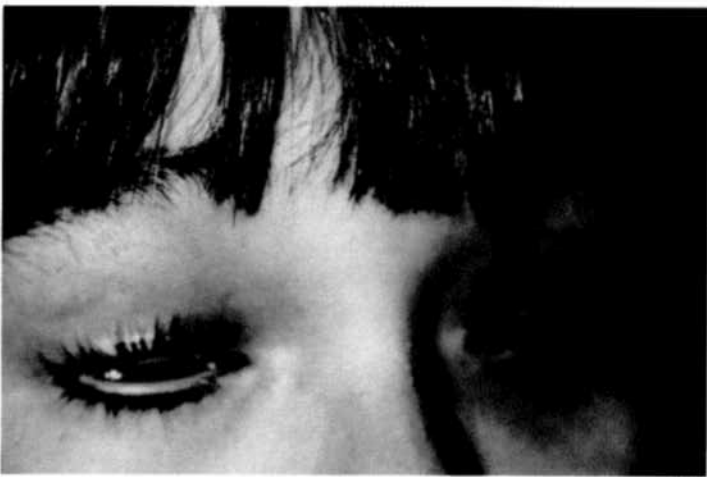
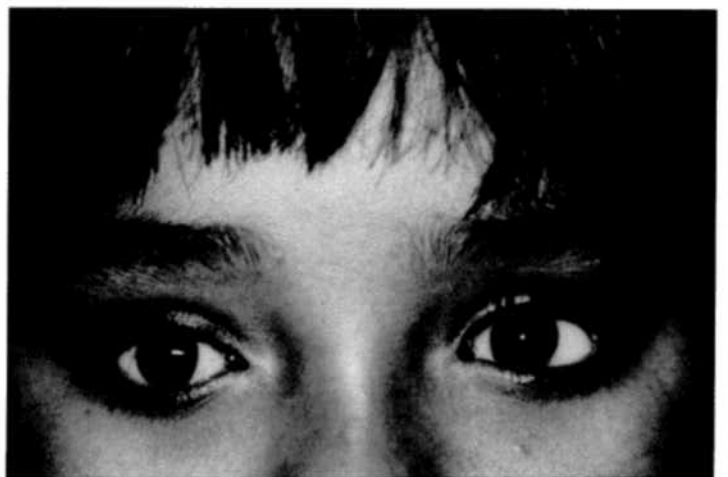
Fig 6.—Same patient after bilateral implantation of hydroxyapatite implants and fitting of ocular prosthesis.



mium: YAG laser (Coherent Medical Group, Palo Alto, California) has resulted in the evolution of intranasal endoscopic laser assisted dacryocystorhinostomy.⁶ The advantages of this surgical approach are (1) the absence of a skin incision, (2) significantly less bleeding, due to the hemostatic properties of the laser, (3) less pain postoperatively due to the micro-invasive nature of the procedure, and (4) return to normal activities the day after surgery.

The procedure involves placing a lacrimal light pipe into the lacrimal sac, and using a videoendoscope attached to a monitor to visualize the junction of the lacrimal sac and the blocked nasolacrimal duct. A laser fiber, passed through a handpiece, is used to create a bypass osteotomy. Silicone stents are then placed through the osteotomy to keep the opening patent (Fig. 2).

The disadvantages of the procedure are the difficulty learning the procedure, and the cost of the laser and ancillary equipment. The societal benefit of earlier return to normal activities, and patient comfort outweigh these disadvantages. (Akin to the difference between laparoscopic and open cholecystectomy).

In our series of 250 operations performed in Hawaii, and a follow-up as long as 5 years, the overall success rate of the procedure is 95% as compared to a 90% success rate for external dacryocystorhinostomy.

Endoscopic Orbital Surgery

In the last decade, the use of the endoscope has become commonplace in orthopedic, general, obstetrical, urological, otolaryngological, thoracic and plastic surgery. Endoscopic surgery is widely accepted in these surgical specialties because the surgery performed through a small incision, allows less invasive surgery and quicker rehabilitation.

Orbital surgery can be performed with the adjunctive use of an endoscope attached to a videomonitor. When combined with transcaruncular and subconjunctival approaches to the medial and inferior orbits, a skin incision can be avoided. Indications for endoscopic-assisted transcaruncular and subconjunctival approaches to the orbit include: 1) the repair of medial and floor fractures; 2) the biopsy and removal of medial and inferior orbital tumors and; 3) two-wall orbital decompression.

The advantages of endoscopic orbital surgery include a smaller incision, decreased need for retraction and disruption of delicate ocular adnexal tissues, better visualization, less bleeding and postoperative pain, and quicker rehabilitation. Teaching new orbital surgical techniques is facilitated with the use of the videoendoscope. Procedures can be videotaped and used subsequently for educational purposes. Shown in Figure 3 and 4 is a patient before and after a three wall orbital decompression.

Other uses of the endoscope in orbital surgery include its potential use in the transnasal endoscopic approach to expose the medial rectus muscle from the annulus of Zinn to the penetration of Tenon's capsule.⁷ A combined transconjunctival and intranasal approach for decompression of the optic canal has recently been described.⁸ In ophthalmological surgery, other uses of the endoscope include ciliary process photocoagulation for end-stage glaucoma⁹, intraocular lens implantation¹⁰, and vitreo-retinal surgery.¹¹

Laser Surgery of the Eyelids and Ocular Adnexa

The use of the CO₂ laser in cosmetic and reconstructive eyelid

surgery is gaining increasing acceptance in the field of oculoplastic surgery. Since the publication on laser eyelid surgery by Baker,¹² not until the advent of ultrapulsed and continuous wave CO₂ laser and the development of laser-safe surgical instruments has this technique become widely used in the United States.

The superpulsed CO₂ laser (Coherent Medical Group, Palo Alto, California) allows for computer controlled vaporization of the epidermis, papillary, and reticular dermis of the thin eyelid skin for removal of superficial lesions and rhytids.¹³ The continuous wave mode of the CO₂ laser allows precise surgical incisions with excellent hemostasis. The advantage of laser eyelid surgery is early rehabilitation due to increased hemostasis and decreased postoperative swelling and bruising.

The continuous wave CO₂ laser in eyelid surgery is used for repair of ptosis, correction of eyelid malpositions such as entropion and ectropion, as well as the removal of benign and malignant eyelid lesions. The pulsed mode of the CO₂ laser is used for the vaporization of seborrheic keratoses, xanthelasma, and the cosmetic improvement of periocular rhytids.¹⁴

The increased cost of the use of the laser is offset by the shorter recovery phase. Postoperative pain after laser eyelid surgery is minimal or absent. It is theorized that laser cauterization of sensory nerves may account for this relative lack of discomfort. Proper ocular protection of the patient, as well as the operating room staff is necessary during laser eyelid surgery.

Advances in Enucleation: The Hydroxyapatite Orbital Implant

An enucleated eye is replaced by placement of an orbital implant to prevent orbital atrophy and superior sulcus deformity. In the past, the orbital implants were spheres of glass, polymethylmethacrylate, silicone, or bone harvested from the iliac crest or rib.

Problems associated with these implants include infection, delayed or immediate rejection and extrusion, as well as lack of motility.¹⁵ Furthermore, the weight of the prosthesis supported by the lower eyelid caused laxity and ectropion of the lower eyelid.

Hydroxyapatite is a new orbital implant material which has a unique interconnected porous matrix derived from marine coral with a mineral composition similar to bone. This orbital implant undergoes fibrovascular ingrowth of the patient's own tissue, becoming truly integrated and less likely to reject, migrate or extrude. The hydroxyapatite implant may be used with other surgical techniques, more complex than standard enucleation.¹⁶

Since the orbital implant integrates with the patient's own tissues the extraocular muscles can be attached directly to the implant, allowing postoperative motility synchronous with the fellow eye.¹⁷

This property of the integrated hydroxyapatite implant offers several advantages to the patient undergoing enucleation: 1) Motility of the prosthesis; 2) Less weight bearing by the lower eyelid which lessens the chances of lower eyelid ectropion; and 3) Less rejection of the hydroxyapatite implant because of the vascular ingrowth. Once the hydroxyapatite implant has vascularized, the implant is drilled and a motility implant sleeve or a motility peg is attached and coupled to the artificial eye (Fig. 5 and 6).

Vascularization of the implant has to be established before the artificial eye is attached. Technetium-99m-methylene diphosphonate (MDP) scintigraphy is a non-invasive method for determining the

vascularity of the hydroxyapatite ocular implant.¹⁸ Another method is the use of a gadolinium DPTA-enhanced MRI with surface coil.¹⁹

After the implant has successfully integrated into the orbit, a motility implant sleeve is drilled into the hydroxyapatite implant and a peg attached to the prosthesis is connected. This final stage couples the implant to the prosthesis and allows for extraocular motility.

The hydroxyapatite implant is popular with oculoplastic surgeons because of the natural eye movement, resistance to extrusion, rare complications, and flexibility in fitting the socket. Hydroxyapatite spheres are contraindicated in those situations other orbital implants are contraindicated; ie, severe trauma with possible orbital infection and orbits with poor vascularization and healing qualities, such as after irradiation, and orbital infection.

Complications of the procedure include infection, conjunctival dehiscence, and rejection of the implant. Currently, research is being done on other types of synthetic orbital implants such as a porous polyethylene implant with properties similar to the hydroxyapatite implant.²⁰

References

- Riefler, D. M. The American Society of Ophthalmic Plastic and Reconstructive Surgery: History of Ophthalmic Plastic Surgery. California, Norman Publishing, 1994, pp. 2-3.
- Katzen, L. B. The history of cosmetic blepharoplasty. In Putterman, A. (ed). Cosmetic Oculoplastic Surgery, New York, Grune and Stratton, 1982, pp. 89-92.
- Smith, B. C. (ed) Ophthalmic Plastic and Reconstructive Surgery, Missouri, C.V. Mosby Company, 1987, pp. 477-489.


- Camara, J.G. Current technique of endoscopic laser assisted dacryocystorhinostomy, American Academy of Ophthalmology Clinical Education Videotapes, 1993.
- Tarbet KJ, Custer PL. External dacryocystorhinostomy: surgical success, patient satisfaction and economic cost. *Ophthalmology*, 1995; 102: 1065-70.
- Gonnering RS, Lyon DB, Fisher JC. Endoscopic laser-assisted lacrimal surgery. *Am J Ophthalmology* 1991; 111: 152-7.
- McKeown CS, Metson RB, Dunya IM, Shore JW, Joseph MP. Transnasal endoscopic approach to expose the medial rectus from the annulus of Zinn to the penetration of Tenon's capsule. *J Pediatr Ophthalmol Strabismus* 1996; 33: 225-9.
- Kuppersmith RB, Alford EL, Patrinely JR, Lee AG, Parke RB, Holds JB. Combined transconjunctival intranasal endoscopic approach to the optic canal in traumatic optic neuropathy. *Laryngoscope* 1997; 107: 311-5.
- Leon CS, Leon JA. Microendoscopic ocular surgery: a new intraoperative, diagnostic and therapeutic strategy. Part II: Preliminary results from the study of glaucomatous eyes. *J Cataract Refract. Surg.* 1991; 17: 573-6.
- Jurgens I, Lillo J, Buil JA, Castilla M. Endoscope-assisted transcleral suture fixation of intraocular lenses. *J Cataract Refract Surg.* 1996; 22: 879-81.
- Eguchi S, Araie M. A new ophthalmic electronic videoendoscope system for intraocular surgery. *Arch Ophthalmol.* 1990; 108: 1778-81.
- Baker SS, Muenzler WS, Small RG, Leonard JE. Carbon dioxide laser blepharoplasty. *Ophthalmology*; 1984; 91: 238-42.
- Goldman MP, Fitzpatrick RE. *Cutaneous Laser Surgery*. Missouri, Mosby, 1994, pp. 85-90.
- Seckel BR. *Aesthetic Laser Surgery*. Boston, Little, Brown and Company, Inc. 1996, pp. 77-81.
- Callahan MA, Callahan A. *Ophthalmic Plastic and Orbital Surgery*. Alabama, Aesculapius Publishing Company, 1979 pp. 42-54.
- Shields CL, Shields JA, De Potter P. Hydroxyapatite orbital implant after enucleation. Experience with initial 100 consecutive cases. *Arch Ophthalmol.* 1992; 110: 333-8.
- Shields JA, Shields CL, De Potter P. Enucleation technique for children with retinoblastoma. *J Pediatr Ophthalmol Strabismus*; 1992; 29: 213-5.
- Baumgarten D, Wojno T, Taylor A Jr. Evaluation of biomatrix hydroxyapatite ocular implants with technetium-99mMDP. *J Nucl Med* 1993; 34: 467-8.
- De Potter P, Shields CL, Shields JA, Flanders AE, Rao VM. Role of magnetic resonance imaging in the evaluation of the hydroxyapatite orbital implant. *Ophthalmology*; 1992; 99: 824-30.
- Rubin PA, Popham JK, Bilyk JR, Shore JW. Comparison of fibrovascular ingrowth into hydroxyapatite and porous polyethylene orbital implants. *Ophthalm Plast Reconstr Surg.* 1994; 10: 96-103.

STRAUB WELCOMES

Robert V. Hollison, Jr., MD

Straub is proud to announce that Dr. Robert Hollison, well-known Honolulu physician, is now practicing medicine at the new Straub Manoa Family Health Center.

Dr. Hollison brings extensive medical expertise to Straub's integrated, patient-focused health care system. And, as Chief of Network Development, he will play a key role in helping Straub to expand its services throughout the islands.



Robert V. Hollison, Jr.,
MD, FACP, FAAFP

Diplomate, American
Board of Family
Medicine

American Board of
Internal Medicine

American Board of
Sports Medicine

American Board of
Geriatrics

Straub

When it really matters

Visit Straub's homepage at <http://www.straubhealth.com>

Straub Manoa Family Health Center

1904 University Avenue, Honolulu, HI 96822 • Phone: (808) 947-4646
Hours: Monday-Friday 8:00 a.m.-4:30 p.m., Saturday 8:00 a.m.-12:00 noon



HAWAII
PATHOLOGISTS'
LABORATORY

The Full Service Lab

Offering Comprehensive
Services in..

- Clinical Pathology
- Surgical Pathology
- Frozen Section Diagnosis
- Pap Smears
- Special Cytology
- Flow Cytometry
- Fine Needle Aspiration
- Bone Marrow Interpretation
- Specimen Photography
- Image Analysis

1301 Punchbowl Street
Honolulu, Hawaii 96813
547-4271 Fax 547-4045