

# Extraction of Lipomas: A simple technique

Greg F Reinking MD\*  
F Don Parsa MD\*

*Benign lipomas are among the most common subcutaneous fatty tumors. They are often solitary, more common in women and occur frequently during the fourth and fifth decades. They usually involve the posterior neck, back and thighs, and the great majority are less than 2 cm in diameter. Malignant transformation is extremely rare, and they usually do not require treatment. However if removal is desired, surgical excision is curative. In this article we present a simple method of resecting large lipomas measuring 4 cm to 10 cm in diameter.*

## Material and Methods

Twenty three patients were evaluated in this study with lipomas measuring 4 cm to 10 cm with a mean diameter of 5.5 cm. All patients were operated on in an outpatient office under local anesthesia, without any intravenous sedation.

Anesthesia was obtained by infiltration with 0.5% Xylocaine mixed with 1:200,000 Epinephrine. In order to maximize the vasoconstrictive effect of Epinephrine, 15 to 20 minutes were allowed to elapse before making a 1.5 cm to 2 cm skin incision either over the fatty tumor or at its periphery. A Kelly clamp was introduced through the incision and by opening and closing the jaws the fatty tissue was broken down while the tumor was squeezed firmly at its base toward the opening. (See Figure and Drawing 1.) This allows gradual extraction of the lipoma with very minimal bleeding. The wound was closed with interrupted 5-0 or 6-0 nylon sutures and dressed with a compression dressing for 24 hours. No limitation in activities was required and at the end of this period the patient was allowed to remove the dressing. Sutures are removed 5 to 7 days later.

## Results

The 23 patients who were treated by this technique were followed over a period of 6 months. Mild ecchymosis was noted in all patients; there were no hematomas or infections. The incisions healed *per primam* and the scars were acceptable.

Two patients developed mild degrees of hypertrophic incisional scars but these did not require further treatment. Ninety percent of patients experienced none to minimal post-operative pain or discomfort. Only 12% of patients used the Tylenol with Codeine No. 3 prescribed for them.

## Summary

During the past decade liposuction has been described as a desirable technique for removal of lipomas<sup>1-4</sup>. However, this requires special, costly equipment including suction apparatus and cannulae. The method of extraction of lipomas measuring 4 cm to 10 cm as described in our series was found to be simple, fast, and free of morbidity. It can be performed in an office setting. This method avoids cumbersome and costly instrumentations that are required with the liposuction technique.

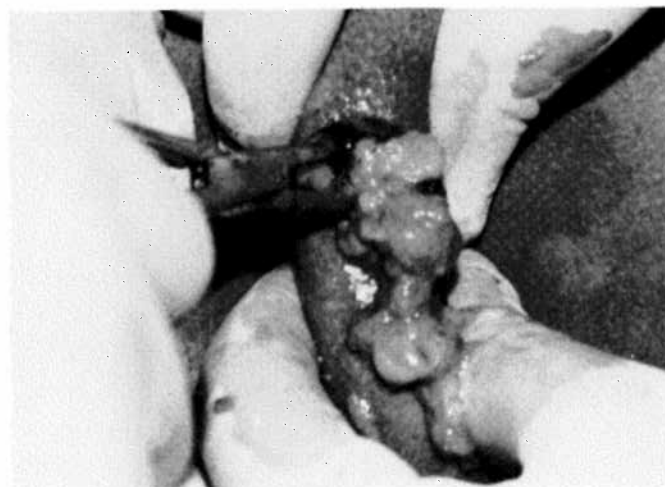


FIGURE 1.  
Photograph and drawing illustrate the squeeze-extraction technique as described in the article.

\* Department of Surgery  
St. Joseph Hospital  
1919 LaBranch  
Houston, Texas 77002

From the Department of Surgery (Plastic), University of Hawaii,  
John A. Burns School of Medicine.

Reprints should be requested from F Don Parsa MD, Department of  
Surgery, 1356 Lusitana Street, Sixth Floor, Honolulu, HI 96813.  
Submitted for publication August 17, 1992

## REFERENCES

1. Lewis CM. The use of lipolysis for unusual diseases. In Hetter GP (ed.) *Lipoplasty*. Little, Brown: Boston, Mass. 1984;323-326.
2. Illouz YG. Surgical remodeling of the silhouette by aspiration lipolysis. *Aesthetic Plast Surg*. 1985;9:7.
3. Hallock EG. Suction extraction of lipomas. *Ann Plast Surg*. 1987;517-519.
4. Nichter LS, Gupta BR. Liposuction of giant lipoma. *Ann Plast Surg*. 1990;24:362-365.