

UPDATE ON RAPA NUI VETERINARY ISSUES AND POTENTIAL HUMAN PUBLIC HEALTH RAMIFICATIONS

Jonathan Arzt DVM, MPVM

INTRODUCTION

My investigation of the state of veterinary affairs on Rapa Nui began in May, 1998 with a search for an economically important disease of dairy cows (papillomatous digital dermatitis, PDD) which had been spreading throughout Chile and many other countries. Though PDD was not encountered on Rapa Nui, it was during that survey that I became aware of the much more serious progressive 20-year epidemic of neurological dysfunction and body-condition wasting among the island's horses and cattle (Arzt and Mount 1999; Arzt 2001). At the time, the syndrome was referred to locally as "vaca loca" (= mad cow disease), and was assumed to represent the widely publicized disease of the same name which had recently led to widespread public panic, direct economic losses of over \$8 billion, and necessitated the destruction of millions of cows in Europe. It quickly became apparent that the syndrome was inconsistent with mad cow disease (bovine spongiform encephalopathy) in several aspects. Samples from affected horses and suspect plants which were collected on four subsequent trips demonstrated that among the horses, the actual cause of the syndrome was ingestion of the plant *Crotalaria grahamiana* (Cho Cho, local name), which had been introduced in the 1980s to control soil erosion (Zizka 1991). The evidence included identification of pyrrolizidine alkaloids (PAs), a class of naturally occurring toxins, in the suspect plants as well as microscopic lesions and alterations of blood chemistry which were typical for exposure to this type of toxin (Arzt et al. n.d.). The most important epidemiological evidence was the temporal association between the onset of the syndrome with introduction and propagation of the plant. Thus, rigorous standards of causality were satisfied to explain the epidemic in horses. Another introduced, toxic plant, *Crotalaria pallida* (Zizka 1991) (Nga Ehe Ehe, local name), which has lower quantities of PAs, may have a contributory role in the described syndromes.

Epidemiologic data suggested that cattle were affected by a syndrome with the same underlying cause; however, proving causality in cattle has been more difficult. While intoxicated horses suffer a readily observable, steadily progressive debilitation, cattle often manifest a less conspicuous, intermittent and recurrent syndrome. This difference may be explained by the greater capacity of the bovine to benefit from gorging on large quantities of available water. Dehydration causes depletion of blood volume, and thus increases concentrations of blood toxins. Typically, affected cows would have mild, intermittent symptoms (predominantly edema with variable neurologic manifestations) for one to three months, and would then disappear from their herd while ranging, presumably having surpassed a threshold beyond which they could no longer physiologically compensate for their intoxication. The diagnostic challenge of the different symptoms in cattle was compounded by the reluctance of ranchers to sacrifice a cow for diagnostic purposes due to the economic value of the animal at slaughter. Cur-

rently, there is no practical diagnostic approach to confirm PA toxicity other than euthanasia (sacrifice) and necropsy (autopsy) examination.

Veterinary Relief International (VRI) is a non-profit charity, which was established in 2000 with the primary purpose of generating funds to support continued animal health and welfare improvement efforts on Rapa Nui. This was necessary, as the granting institutions that typically fund veterinary fieldwork do not readily fund this type of small-scale veterinary service and research. The establishment of VRI has produced sufficient funding to allow annual trips to island in order to:

- 1) provide free veterinary primary care,
- 2) consult with politicians and ranchers regarding reforming attitudes and approaches to animal care,
- 3) assist land-owners with removal of toxic plants from their pastures, and
- 4) continue investigation of the extent of ramifications associated with consumption of toxic plants by livestock.

Our intention is to expand efforts in the manner described below as funds become available.

PYRROLIZIDINE ALKALOID INTOXICATION EXPLAINED

Pyrrolizidine alkaloid toxicosis (toxic poisoning) of livestock has been described in several nations (McLean 1970). In the western United States, toxicity in livestock is most commonly associated with ingestion of *Senecio jacobaea* (tansy ragwort) and *S. vulgaris* (Riddell's groundsels) (Pearson et al. 1991). Other genera of plants known to contain PAs include *Crotalaria* (rattlebox), *Amsinckia* (fiddleneck), and *Heliotropium* (heliotrope) (Mattocks 1986). A plant may produce up to six distinct PAs; toxicity varies among different PAs. Plants containing PAs are thought to be poorly palatable to livestock, and are typically consumed when other forage is unavailable, as is often the case on Rapa Nui. Pyrrolizidine alkaloids are known to affect humans with similar effects as seen in livestock. Human PA poisoning has occurred as epidemics and sporadic cases associated with ingestion of "bush tea" as well as from a wide variety of herbal medicinals (Stickel et al. 2000; Coulombe 2003). Though PAs are detectable in the milk of intoxicated animals, there is conflicting evidence regarding toxicity associated with consumption of this milk (White et al. 1984).

The complexity of PA-intoxication syndromes begins with the fact that PAs themselves are not toxic, per se. Ingested PAs are converted by enzymes in the liver of the consumer into another class of chemical, pyrroles, which are the true toxins (Mattocks 1986). Pyrroles are highly reactive and affect cells by binding to DNA and proteins involved in cell division (Coulombe 1999). Cells of the liver are preferentially affected, as they are the main source of production of pyrroles which are subsequently disseminated through the blood. Intoxication typically results in cirrhosis (chronic liver failure), however the tox-

ins may also induce irreversible lesions in kidneys and lungs. The characteristic stuporous behavior of PA-intoxicated animals is a manifestation of hepatic encephalopathy (secondary brain toxicity resulting from inability of the liver to clear endogenous toxins from the blood). The specific pathophysiology of hepatic encephalopathy is not completely understood, however increased blood concentration of the metabolic byproduct, ammonia, is the most commonly recognized pathway by which neurological function is altered. Edema (abnormal collections of body water) is a non-specific symptom which may occur with liver failure regardless of the underlying cause.

Another important aspect of PA toxicosis is the irreversibility of the effects of the toxins on target organs. By the time animals begin to manifest symptoms of intoxication, permanent damage has been done, and death is nearly inevitable. In humans and household pets, various modes of therapy can improve quality of life during terminal cirrhosis, but these therapies are palliative rather than curative and, regardless, are not practical in livestock species. Human cirrhotics, like PA-intoxicated animals, experience confusion, dementia, nausea, and stupor progressing to coma (Fauci 1998). Based on the animals' suffering and lack of any means of remedy, it is the veterinarian's responsibility to encourage humane euthanasia of such animals.

PROVING PA TOXICOSIS IN RAPA NUI CATTLE

In January, 2003 an intensive effort was undertaken to solidify suspicions that the syndrome of neurological dysfunction and edema among Rapa Nui cattle was the result of *Crotalaria* ingestion and PA-intoxication, like the similar disorder affecting the island's horses. Eleven cows with varying extents of the described symptoms were identified and followed by daily visual tracking. In nine of 11 cases, the animals' owners refused to sacrifice their cow, and all nine disappeared from their herd within two weeks (presumably died) and could not be located despite extensive effort. With just two days left on the island, two owners consented to euthanize their suffering cows for the greater importance of determining the cause of the bovine syndrome. During necropsy, both animals had gross evidence consistent with PA-poisoning including small, firm livers and edema of body cavities and connective tissues. Microscopic examination of the tissues at Colorado State University Veterinary Diagnostic Laboratory confirmed the diagnosis of PA-toxicity in these animals.

A skeptic could, justifiably, criticize making broad conclusions based on analysis of tissues from just two animals. Thus, it is important to be somewhat conservative in the following logical pathway. Facts:

- 1) Large numbers of cattle on Rapa Nui suffer a syndrome consisting of progressive neurological dysfunction, edema, and body condition wasting.
- 2) Such syndromes have previously been well-documented as resultant from ingestion of PA-containing plants.
- 3) Rapa Nui cattle are frequently seen ingesting two species of plants, which are now known to contain high levels of PAs.
- 4) Two Rapa Nui cows with typical symptoms of the

described syndrome had pathologic lesions consistent with the textbook description of PA-intoxication.

- 5) Epidemiologic data supports the notion of widespread bovine PA-poisoning on Rapa Nui.

Hypothesis: The widespread loss of cattle on Rapa Nui associated with the described syndrome is attributable to PA intoxication associated with ingestion of *Crotalaria* species. Despite the room for purist conservatism, most investigative diagnosticians would support this hypothesis based on the data collected to date.

POTENTIAL OF HUMAN HEALTH RISKS ASSOCIATED WITH INGESTION OF RAPA NUI BEEF

Several difficulties confound assessment of the likelihood of human health risk associated with consumption of beef from cattle ingesting PAs, despite the known facts that PAs are toxic to humans and that several PAs have been shown to be carcinogenic in animals. Several variables affect the toxicity of a specific PA to a specific animal (humans included) including species, age, nutritional status, gender, and the quantity and frequency of ingestion (Colegate et al. 1998). Thus, proven toxicity of Cho Cho to a somewhat malnourished, chronically dehydrated, adult, steer could not be extrapolated to determining the potential effect on a six-month fetus in a relatively well-nourished Rapanui woman. An advantage to the human consumer is that the concentration of alkaloid (and pyrrole metabolites) would be much lower in the beef relative to the cow's plant meal. However, the human has the disadvantage that minute quantities of toxin might be ingested over the course of 50 years or more.

Such a determination is sufficiently challenging under ideal laboratory exposures in which many variables can be controlled. The situation on Rapa Nui includes many factors that make assessment far more complex. Cattle on Rapa Nui graze amongst the toxic plants every day of their lives. Animals' affinity for the plants will vary seasonally and with individual animals' behavioral inclinations. Additionally, the concentration of PAs in the ingested plants varies seasonally and with geographic location. Thus, it is extremely variable and unpredictable how long toxins would persist in the blood and beef of a cow subsequent to ingestion of a PA-containing meal. A cow with profound neurological symptoms may have advanced cirrhosis but minimal toxin in its tissues, while a completely asymptomatic animal may have just gorged on Cho Cho and have higher toxin levels. The effects of long term low dose exposure to PAs, as is occurring in the Rapanui human population have, to date, not been thoroughly examined. Detection of pyrroles in the tissues of PA-intoxicated animals is extremely difficult even under ideal laboratory conditions. Development of technologies to detect extremely small quantities of pyrroles is currently an active field of research at the USDA Poisonous Plant Research Laboratory in Logan, UT (Stegelmeir, personal communication). Improved techniques will, likely, become available within the next five years.

A "bottom line" assessment at present would have to suggest that the current situation warrants further investigation, but that definitive human health risk is not currently established. Practical application of the currently available knowledge is that

no cow with symptoms of neurologic dysfunction or edema should be consumed by humans. Additionally, liver and kidney should not be consumed from any cow on Rapa Nui, as these organs may have higher toxin levels. The next logical steps in assessing human health risk are twofold. An epidemiological survey looking for evidence of human PA toxicosis at the Rapa Nui hospital is indicated and would be useful if such data is available. A large-scale screening of bovine tissues for pyrrole residues is also important and will be part of VRI's ongoing investigation as this technology becomes available.

OVERPOPULATION AND HERD MANAGEMENT

Accurate data describing quantities of animals on Rapa Nui is not currently available; however, prevalent malnutrition, dehydration, and neglect of livestock and companion species are readily apparent without census or veterinary consultation. The present number of animals might be sustainable if adequate supplemental feed and water could be provided regularly. As provision of such supplements is not currently feasible, it is an intuitive conclusion that efforts should be exerted to encourage decreasing quantities of all domestic species on Rapa Nui. This may be accomplished by a combination of selective (limited) breeding and culling of sick or debilitated animals. It is the author's opinion that populations of domestic species on Rapa Nui exceed quantities that are necessary for human sustenance and draught. This further supports a plan of population mitigation as requisite to any attempt at animal welfare improvement.

Lack of managed confinement of livestock species continues to create problems relating to animal health and impact of grazing animals upon the environment. Such impact is of greatest concern as related to damage of archaeological sites. Livestock still frequently graze the plazas of Ahu Tongariki, Ahu Akivi, and Ahu Tahai. Medical concerns arising from animals' free-ranging include exposure to toxic plants, lack of animal health monitoring, and inability to provide routine medications, feed supplements, and supplemental water.

POSITIVE DEVELOPMENTS

An important aspect of VRI's work on Rapa Nui has been providing free veterinary services and consultations to local ranchers regarding implementation of modern herd management practices. The most important aspects of modernization are confinement of animals within fenced pastures and reduction of herds of cattle and horses. Confinement has several advantages including prevention of toxic plant consumption and ability to provide supplemental feed and water. When sustenance is poor, a smaller herd will have increased productivity, as greater resources will be available to each individual animal. Confinement and herd reduction are, both, important in easing ongoing tensions among ranchers, park managers, and archeologists regarding public roaming of livestock.



Pyrrolizidine alkaloid intoxicated horse near Rano Raraku. The front limb wide-based stance is a typical finding in animals with brain dysfunction secondary to liver failure (hepatic encephalopathy) and is thought to represent compensation for dizziness.

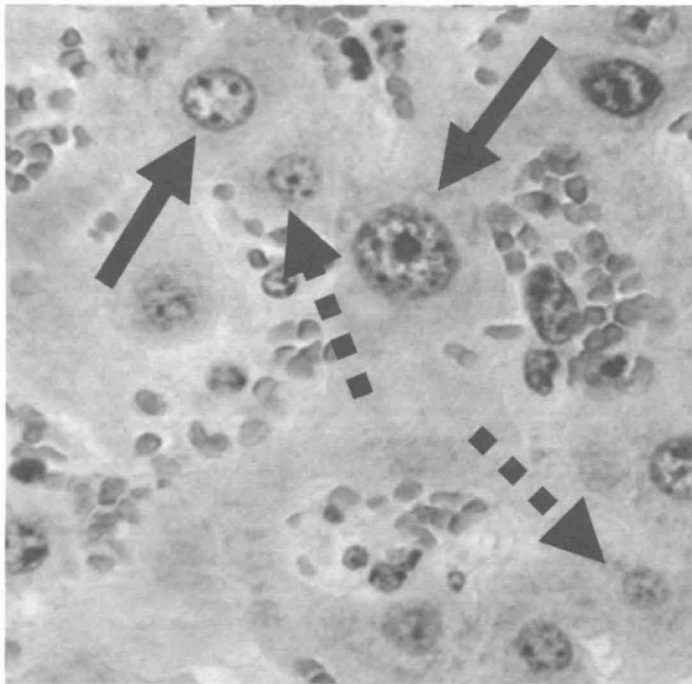


Cattle grazing the plaza of Ahu Tongariki. Livestock continue to graze important archaeological and historic regions despite the construction of retaining walls intended to exclude roaming animals.

In 2003, 4 of 23 (17%) surveyed ranchers indicated utilization of varying extents of confinement of cattle and regional elimination of Cho Cho with (subjectively) improved overall health. This is a marked improvement from 1999 when only 1 of 28 (4%) ranchers was limiting ranging of cattle. Obviously, the hope is that over the course of further efforts, more ranchers will learn and benefit from the examples of their peers and the advice of VRI veterinarians. The challenge in this matter is overcoming the well-established practice of free ranging of cattle. Additionally 18 of 23 (78%) ranchers indicated improved overall health of their animals after receiving de-worming medications and vitamin supplements from VRI. Though this is encouraging, the services currently provided by VRI are still inferior to the most basic management practices in the United States. Provision of such preventative medicine practices will expand over coming years with the goal of continually improving livestock welfare on Rapa Nui.

Another encouraging development is the recent establishment in of an office of veterinary affairs within


the Hanga Roa municipal government. An important goal of this office is to provide free vaccination and contraceptive injections for dogs and cats in order to improve health and limit overpopulation in these species. Additional basic veterinary services are offered by fee basis, but seem underutilized due to cost and lack of knowledge of availability. Though this is a step in the right direction, the office is understaffed and inadequately



Photomicrograph (~400X) of bovine liver from Rapa Nui cow affected by the widespread syndrome of neurologic dysfunction and edema. Giant, bizarre liver cells (solid arrows, hepatic megalocytes) are the hallmark finding in pyrrolizidine alkaloid intoxication. Normal liver cells (broken arrows).

funded to thoroughly address its goals. As funds become available, it is the intention of VRI to subsidize these efforts in order to more thoroughly control overpopulation and neglect of Rapa Nui's small animal species.

The only complete solution to the Cho Cho situation is the total eradication of the plant from Rapa Nui. It is beyond the scope of expertise of this author to estimate the cost and feasibility of such an effort given the profuse spread of the plant. In addition to encouraging and assisting ranchers with regional elimination of the plant from private land, meetings with officials in various branches of the local government have had some promising results. Tractors are routinely used to clear the plant as it encroaches upon the Anakena road (primarily to diminish the visibility hazard to vehicles). Awareness that the plant poses veterinary and possibly public health threats has motivated the government to pledge that greater quantities of Cho Cho will be cropped during routine road clearing efforts. Additionally, the plant has been cleared and replaced by small trees in the area surrounding the parking area at Rano Raraku. Though such efforts will not solve the problem posed by the plant, they contribute to decreasing the bulk of toxic plants on Rapa Nui and increasing public awareness of the proven and potential problems associated with such plants.



Veterinary Relief International veterinarian demonstrating proper technique for administering de-worming medication (near Ovahe, 2003).

The 2003 trip also provided the first opportunity to seriously discuss the notion of utilizing immunocontraception in Rapa Nui horses as a humane approach to population control. This approach has been used successfully in feral horses in the southwestern US public lands and east coast barrier islands (Turner and Kirkpatrick 2002). Using immunocontraception, a single injection could prevent a mare from conceiving for five years or longer with no adverse affects to her health. Not surprisingly, this concept initially met resistance from ranchers, as it conflicts with the prevalent notion that more foals are always desirable. However, when it was explained that great energies are lost to reproduction and lactation and that a mare treated with such a product could be ridden and worked for many years longer than if she carried and nursed foals, several ranchers consented and requested contraception for their mares. The municipal government also approved the project. The problem is that such products are quite expensive and it is uncertain if sufficient animals could be treated to have a significant impact on the prolific Rapa Nui equine population.

CONCLUSIONS AND FUTURE PROJECTS

The two main veterinary issues on Rapa Nui continue to be irresponsible management of livestock and the fatal syndrome affecting horses and cattle caused by ingestion of Cho Cho. Both issues are complex and require collaborative efforts beyond the veterinary profession to affect remedies. I am encouraged by the fact that in a relatively short period of time I have been able to create moderate public awareness of these issues which, in my experience, had previously been largely overlooked and/or tolerated. Changing the long-established mentalities of ranchers and politicians is far more challenging than diagnosing a disease. Yet, progress is coming, albeit slowly, in all realms. For the veterinarian, a significant conflict exists on Rapa Nui between the goals of improving the health of the resident animals without thereby potentiating the problem of overpopulation. A wonderful solution would be the establishment of a cooperative ranch at Fundo Vaitea which would provide ranchers an area to enclose their animals on rangeland where poisonous plants could be removed, supplemental feed and water could be pro-

vided, and damage to environment and archaeological sites could be avoided. Though I have suggested such a project to various groups, clearly there are louder voices that will determine the course of land reform on Rapa Nui. The point, though, is that while a gringo veterinarian can make recommendations and utilize various resources at his disposal, ultimately the Rapanui will have to exert significant efforts to resolve the problems affecting the animals of Rapa Nui.

Veterinary Relief International will continue to investigate the PA situation with increased effort directed towards determining the potential risk to humans. We will continue to provide free veterinary services by returning to the island as frequently as funding allows. Hopefully, by collaborating with the municipal government, we will be able to establish a more permanent means of providing such services. The equine immuncontraception project will begin when funding and collaboration become available. One aspect of these endeavors has become abundantly clear: the more time I invest in veterinary projects on Rapa Nui, the more projects I have to embark upon.

ACKNOWLEDGEMENTS

The efforts described herein would not have been possible without local assistance from Retu Tepano and Hotu Araki Tepano to whom I, and the animals of Rapa Nui, are indebted. I also wish to thank the Easter Island Foundation for providing this forum in which to communicate my findings with a concerned and non-medical community. Parties interested in obtaining more detailed information regarding the described projects are encouraged to contact the author.

Correspondence: Jonathan Arzt, D.V.M., M.P.V.M.
Veterinary Relief International
3235 Davis Ranch Road
Bellvue, CO 80512
(970) 472-0182
jjarzt@earthlink.net

REFERENCES

- Arzt, J. and M. E. Mount. 1999. Hepatotoxicity Associated with Pyrrolizidine Alkaloid (*Crotalaria* spp.) Ingestion in a Horse on Easter Island. *Vet Hum Tox.* 41(2):96-99.
- Arzt, J. 2001. Livestock Related Problems on Rapa Nui; Assessment and Proposed Mitigation Strategies. *Rapa Nui Journal.* 15(1):27-30.
- Arzt, J., S. Couto, B. Puschner, J. Zinkl, D. H. Gould and M. E. Mount n.d. (manuscript in preparation). Enzootic Equine and Bovine Pyrrolizidine Alkaloid (*Crotalaria grahnamiana*) Toxicosis on Rapa Nui (Easter Island).
- Colegate, S. M., J. A. Edgar and B. L. Stegelmeier. 1998. Plant-associated Toxins in the Human Food Supply. *Natural Chemicals.*
- Coulombe, R. A. 1999. Pyrrolizidine Alkaloids Crosslink DNA with Actin. *Tox Appl Pharm.* 154:198-202
- Coulombe, R. A. 2003. Pyrrolizidine Alkaloids in Foods. *Adv Food Nutr Res.* 45:61-99.
- Fauci, A. S. 1998. *Harrison's Principles of Internal Medicine*, 14th ed. :2453.
- Mattocks, A. R. 1986. Toxicology of Pyrrolizidine Alkaloids in Animals. *Chemistry and Toxicology of Pyrrolizidine Alkaloids.* London: Academic Press. :191-219
- McLean E. K. 1970. The Toxic Actions of Pyrrolizidine Alkaloids. *Pharmacol Rev.* 22:429-483.
- Pearson, E. G., C. Meyer et al. 1991. Clinicopathologic Studies of Tansy Ragwort Toxicosis in Ponies: Sequential Serum and Histopathological Changes. *Eq Vet Sci.* 11:261-271.
- Stegelmeier B. L. Personal communication.
- Stickel, F., G. Egerer and H. K. Seitz. 2000. Hepatotoxicity of Botanicals. *Public Health Nutr.* 3(2):113-24
- Turner, A. and J. F. Kirkpatrick. 2002. Effects of Immuncontraception on Population, Longevity and Body Condition in Wild Mares (*Equus caballus*). *Reprod Suppl.* 60:187-95
- White, R. D. et al. 1984. Mutagenic Responses. *J Anim Sci.* 58:1245-1254.
- Zizka, G. 1991. *Flowering Plants of Easter Island.* Frankfurt: Palmengarten, :45.

Rongorongo Studies

A Forum for Polynesian Philology



Annual Subscription NZ \$20 or US \$15

Contact Dr Steven Roger Fischer
PO Box 6965, Wellesley Street
Auckland 1, New Zealand
rongosf@internet.co.nz

HAUMAKA TOURS

Ramón EDMUNDS and Josefina NAHOE
Correo Isla de Pascua
RAPA NUI, Chile

e-mail: haumaka@entelchile.net
voicemail/fax for USA and Canada: (310) 754-6000 x1548
phone/fax on Rapa Nui: (011-56-32) 100-274

Look for our website! <<www.HaumakaTours.com>>