

# Severe Hemorrhagic Complication of Talc Pleurodesis for Idiopathic Pleural Effusion

Brandon Hirota MSII, Michelle M. Nguyen MSIV, Shigeo Irimajiri MD, Jennifer Choi MSII, and Jinichi Tokeshi, MD

## Abstract

*Talc is a commonly used sclerosing agent for pleurodesis. However, there have been recent reports of a number of complications associated with the use of talc. Although there is significant data regarding the respiratory complications associated with talc, reports of bleeding complications are extremely rare. We present the case of a 78 year-old man who was treated with talc pleurodesis for recurrent pleural effusion and subsequently developed a massive hemothorax, a rare complication.*

## Introduction

Management of idiopathic pleural effusion is a controversial topic. The effusion may resolve spontaneously or be treated with pleurodesis. Talc pleurodesis is a commonly employed technique for the treatment of spontaneous pneumothorax and recurrent pleural effusion. The use of talc as an agent for pleurodesis is ascribed to Bethune, who used it in preparation for lung lobectomy in 1935.<sup>1</sup> Due to impurities associated with earlier preparations of talc, tetracycline was the agent of choice in the United States until the 1980's when its production was discontinued for commercial reasons. As tighter quality control was placed on the production of talc, its popularity increased making it the agent of choice for chemical pleurodesis. Preference for talc as a sclerosing agent is based upon its cost, availability, ease of use, and effectiveness in creating pleural adhesions.<sup>2,3,4</sup> Regardless of its high degree of effectiveness, talc is not the perfect sclerosing agent for pleurodesis. Its use is associated with a number of complications. We present a case of hemothorax following talc pleurodesis in an elderly male treated for idiopathic, recurrent pleural effusion.

## Case Report

A 78 year-old Japanese-American man with a 30-pack-year history of smoking, asbestos exposure, coronary artery disease with two coronary artery bypass grafts (CABG), hypertension, diabetes and intermittent swelling of his lower extremities was stable in his usual state of health until the day of admission, when he presented to his primary care physician for regular checkup. Upon examination, his vital signs were

within normal limits. He was noted to have crackles and diminished breath sounds over his right lung field as well as bilateral pitting edema extending up to his knees. Chest x-ray (CXR) revealed right-sided pleural effusion filling half of the lung field, and the patient was subsequently admitted. Laboratory studies revealed: hemoglobin 10.3 g/dL, hematocrit 30%, platelet 136,000/mm<sup>3</sup>, sodium 126 mEq/L, total protein 5.5 g/dL, and albumin 5.0 g/dL. Cardiac enzymes and urinalysis were both within normal limits. Furosemide was started on admission, and pitting edema subsequently resolved. Echocardiogram showed normal ejection fraction and left ventricular wall motion. Follow up CXR was performed on the second hospital day and showed no improvement in pleural effusion (Fig 1). On the third hospital day one liter of yellow, turbid fluid was removed by thoracentesis and analysis revealed: pH 7.513, RBC 3373/mm<sup>3</sup>, WBC 110/mm<sup>3</sup> with 81% neutrophils and 10% lymphocytes, glucose 111 mg/dl, LDH 105 U/L, protein 3.3 g/dl, protein fluid/serum ratio of 0.56, with the presence of histiocytes, mesothelial cells, and lymphocytes. Gram stain and culture of the fluid were negative.

On hospital day 5, CXR revealed reaccumulation of effusion and aspirin was discontinued. On hospital day 7, his PTT, PT, and INR were 38 sec, 12.3 sec, and 1.2 respectively. The patient underwent video-assisted thoracoscopy (VATS) that revealed diffuse, fibrotic, whitish plaques in his parietal pleura, and a small posterior pleural mass. Biopsy of the pleural plaques and the mass showed numerous hyperplastic mesothelial cells admixed with fibrin. Malignancy was not identified. Twelve grams of talc was insufflated throughout the pleural surfaces to produce pleurodesis. The morning after the procedure, the patient was noted to have a temperature of 100.7°F, blood pressure of 90/40, and altered mental status. Arterial blood gas revealed: pH 7.395, PO<sub>2</sub> 60 mmHg, PCO<sub>2</sub> 42.6 mmHg, HCO<sub>3</sub><sup>-</sup> 26.4 mmol/L, BE 2, and SaO<sub>2</sub> 86.6% on 2L oxygen. Hemoglobin dropped to 8.5 g/dL, but returned to baseline of 10 g/dL after transfusion of four units of packed red blood cells. Chest tube was left in place for three days and a total of 500 ml of

## Authors:

University of Hawaii, John A. Burns School of Medicine (B.K.H., M.M.N., J.C.)

Kuakini Medical Center Family Practice Residency Program (S.I.)  
Associate Professor, University of Hawaii, John A. Burns School of Medicine (J.T.)

## Correspondence to:

Jinichi Tokeshi MD  
1451 S. King St., #209  
Honolulu, HI 96814

sanguineous fluid was collected. On day 7 CBC revealed white cell count of 11,000 with 57% segmented neutrophils and 32% bands. After removal of the chest tube the patient was noted to have diminished breath sounds on the right and recurrence of effusion was suspected, thus a CT scan was performed and revealed a massive heterogeneous effusion in his right thorax, suggestive of either a hematoma or empyema (Fig. 2). On hospital day 17, right thoracotomy showed calcified and scarred parietal pleura and diffuse hemorrhagic visceral pleura. During the procedure, 900 ml of clotted blood was evacuated from the pleural space. The patient developed acute respiratory failure post-operatively and required mechanical ventilation in the ICU. Chest x-ray revealed reaccumulation of significant intrathoracic and subcutaneous hematomas. A total of 1800 ml of sanguineous fluid was drained through the chest tube, and several units of packed red blood cells, fresh frozen plasma, and platelets were transfused. On hospital day 31 the patient was transferred to a skilled nursing facility for rehabilitation.

## Discussion

Chemical pleurodesis involves the introduction of a sclerosing agent into the pleural space inducing fusion of the visceral and parietal pleura to prevent recurrence of pneumothorax or pleural effusion. Currently, talc is the agent of choice for producing pleurodesis in the United States. Talc is thought to produce pleural adhesions by stimulating a local inflammatory response, causing mesothelial cell injury and fibroblastic proliferation, and decreasing fibrinolytic activity.<sup>5,6</sup> Several studies have found talc's ability to produce adhesion to be equal or superior to other sclerosants.<sup>3,4,7,8</sup> Although talc is believed to be one of the safest, cheapest, and most effective agents for promoting pleural adhesion, there are a number of reported complications.

Minor complications such as tachycardia (33%),<sup>9</sup> fever (2.8-24%),<sup>9,10,11,12</sup> and dyspnea (7-12%)<sup>9,10</sup> have been observed. Hypoxia and hypotension have also been reported with cases ranging between 10-12%<sup>10,13</sup> and 1-12% respectively.<sup>11,14,15</sup> Other major complications that have been reported include prolonged drainage (4%),<sup>13</sup> air leaks (0.1-2.4%),<sup>12,15</sup> re-expansion pulmonary edema (2.2 - 12.3%),<sup>10,12</sup> empyema (1.2 - 4%),<sup>10,12,13</sup> and acute respiratory distress syndrome (1.3% - 9%).<sup>10,12,14,15,16</sup>

Our patient had similar complications including fever, hypoxia, and hypotension. He also developed hemorrhagic pleuritis, which has not been extensively discussed in the literature. We conducted a Medline literature search, limited to English language and found only three reports of bleeding complications associated with talc pleurodesis. One retrospective study showed that of 85 patients undergoing talc pleurodesis, only one developed postoperative bleed-

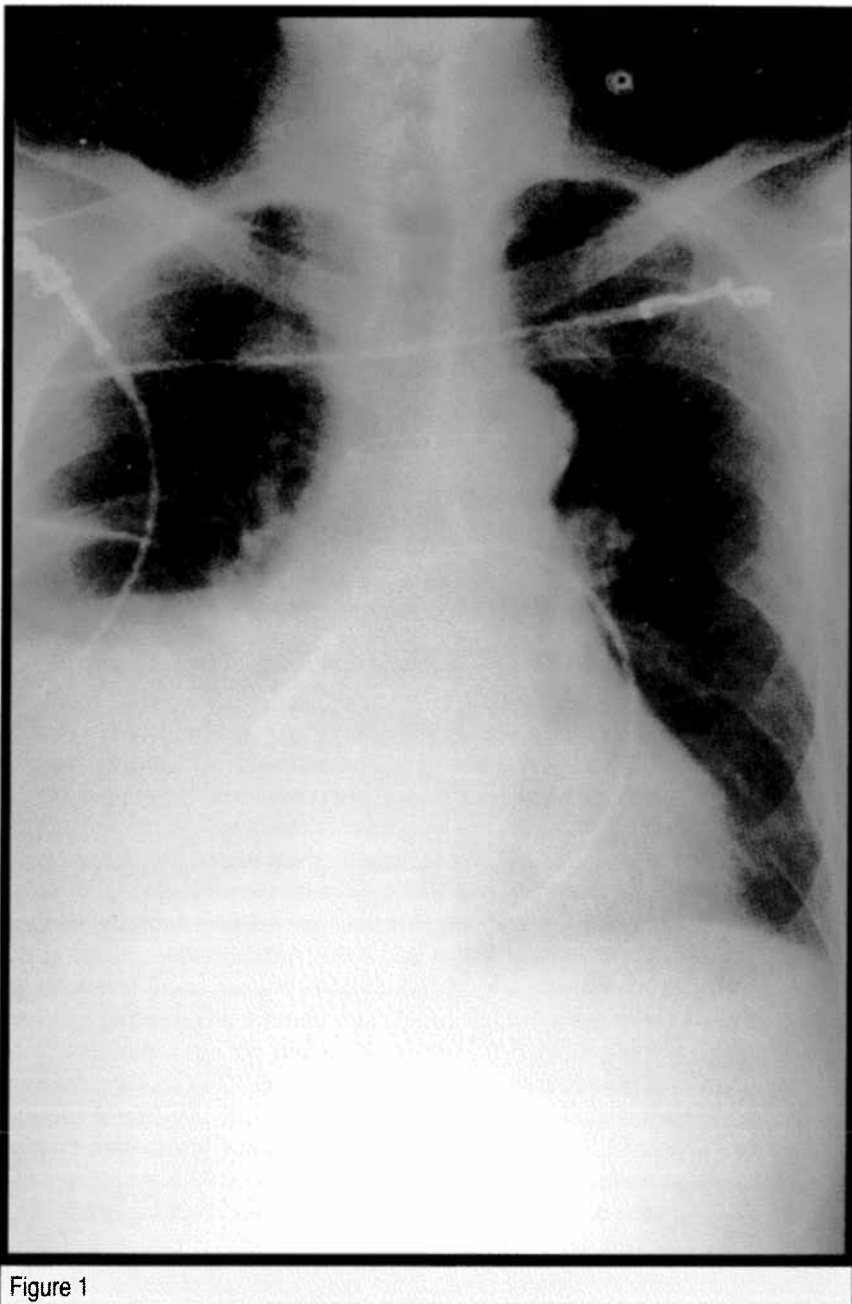


Figure 1

ing.<sup>13</sup> Another study by Cardillo et al reported that 1 out of 690 patients developed hemorrhagic complications.<sup>15</sup> The third study reported that 2 out of 614 patients developed postoperative bleeding.<sup>12</sup> None of these three studies discussed the bleeding complication in detail.

The exact cause of the hemorrhagic pleuritis in our patient is unknown. We believe that this patient's coagulation profile, asbestos exposure, and pleural biopsy did not directly contribute to his post-operative bleeding. Coagulopathy was not a major concern in this patient since he did not develop postoperative bleeding with his previous CABG surgeries. The patient had no history of warfarin use, his PT and INR were within normal limits, and aspirin was discontinued two days prior to surgery. Exposure to asbestos may have contributed to this patient's pleural effusion. However, it does not seem to be solely responsible for the hemorrhagic pleuritis. Diffuse, fibrotic, whitish plaques consistent with previous asbestos exposure were noted on the parietal pleura during VATS. However at the time of thoracotomy on hospital day 17, bleeding was observed from the visceral pleura, and not the parietal pleura. In addition, Aelony et al did not observe hemorrhagic

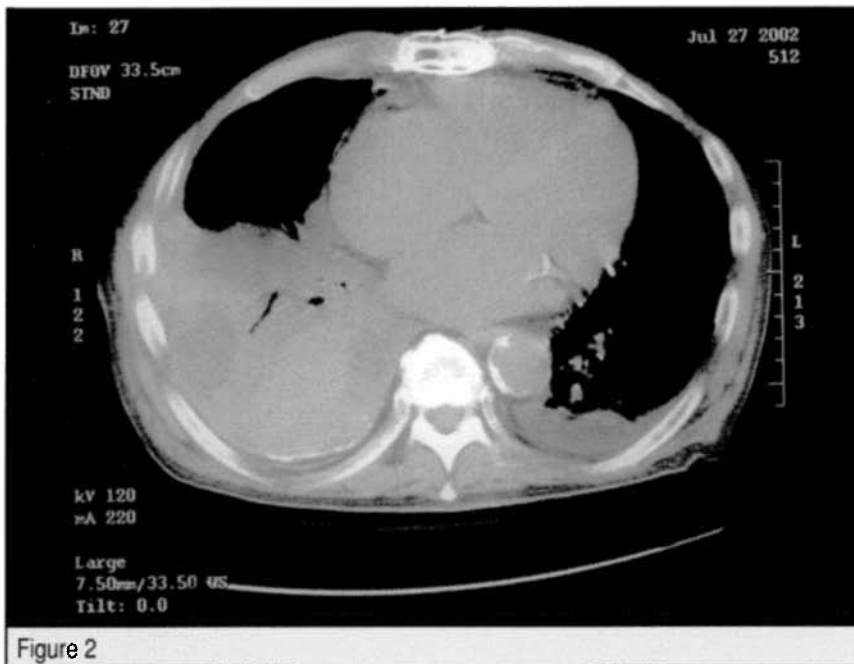

Figure 2

complications in three patients with asbestosis injury who underwent talc pleurodesis.<sup>17</sup> Since the bleeding in this patient came from the visceral pleura, the biopsy, which was performed on the parietal pleura, did not contribute to this patient's bleeding complication. The safety of video-assisted thoracoscopic pleural biopsy is supported by the study by Allen et al, which demonstrated no postoperative bleeding complications in 86 patients who underwent the procedure.<sup>13</sup>

Possible causes of hemorrhagic complications are the talc itself, the method of talc application, and the amount of talc used. Although one animal study demonstrated that intrapleural talc administration does not cause hemothorax, several other studies suggest that talc could cause damage predisposing a patient to hemorrhagic complications.<sup>18</sup> Studies in rabbits and rats have shown that talc distributes systemically after intrapleural administration.<sup>19,20</sup> In another study, an autopsy of a patient who died from acute respiratory distress syndrome showed talc particles deposited in ipsilateral and contralateral lung, brain, liver, kidney, heart, spleen, and skeletal muscle.<sup>12</sup> Thus, talc particles could have entered the circulation and caused damage to the vascular endothelium resulting in bleeding complications.

Talc delivered by insufflation may contribute to hemorrhagic pleuritis. Our patient and two other reported cases developed postoperative bleeding after talc insufflation.<sup>12,15</sup> The method of talc delivery is unknown in another case mentioned by Allen et al.<sup>13</sup> In contrast, an animal study comparing anatomic and histopathologic results of four different methods of pleurodesis including thoracoscopic talc insufflation, talc slurry abrasion, focal gauze abrasion by limited thoracotomy, and mechanical abrasion by thoracoscopy, observed no hemorrhagic complications.<sup>18</sup> However, the study's sample size of 10 may have been too small to observe any bleeding complications.

Lastly, the amount of talc used may play a role in the development of the bleeding complication. Our patient had 12 grams of talc insufflated to achieve pleurodesis. However, postoperative bleedings have been reported at different doses. Bleeding complications were reported in Milanez et al's study, which used only 2 grams of talc.<sup>12</sup> The study by Cardillo who reported one case of postoperative bleeding used 5 grams of talc.<sup>15</sup> The amount of talc used is unknown in the study conducted by Allen et al. who reported one case of postoperative bleeding. Rehse et al used 10 grams of talc slurry and they did not observe any postoperative bleeding.<sup>10</sup> Since the occurrence of bleeding complications varies with different doses of talc, it

is unclear whether the 12 grams of talc used for this patient is directly responsible for the development of hemorrhagic pleuritis.

## Conclusion

Using talc as a sclerosing agent for pleurodesis is a commonly accepted practice. In this case report, a 78 year-old man who underwent thoracoscopic talc pleurodesis developed massive bleeding. Postoperative bleeding is a rare complication of talc pleurodesis. Although the exact mechanism leading to this patient's massive hemorrhage remains unknown, the etiology is most likely multifactorial. It may be due to the talc itself, the method of talc application, and the amount of talc used. Our patient's asbestos exposure and slightly prolonged PT/INR are probably of less importance. Although talc's efficacy and common complications are well documented, it is important to consider postoperative bleeding as a possible severe complication. Further studies are needed to better understand the safety and complications of talc pleurodesis.

## References

- Bethune N. Pleural poudrage: a new technique for the deliberate production of pleural adhesions as a preliminary to lobectomy. *J Thoracic Surg.* 1935; 4:251-261.
- Colt H, Russack V, Chiu Y, Konopka R., Chiles P, Pedersen C, Kapelanski D. A comparison of thoracoscopic talc insufflation, slurry and mechanical abrasion pleurodesis. *Chest.* 1997; 111(2):442-448.
- Zimmer P, Hill M, Casey K, Harvey E, Low D. Prospective randomized trial of talc slurry vs bleomycin in pleurodesis for symptomatic malignant pleural effusions. *Chest.* 1997; 112(2):430-434.
- Ong K, Indumathi V, Raghuram J, Ong Y. A comparative study of pleurodesis using talc slurry and bleomycin in the management of malignant pleural effusions. *Respirology.* 2000; 5:99-103.
- Van den Heuvel. Talc-induced inflammation in the pleural cavity. *Eur Respir J.* 1998; 12:1419-1423.
- Antony V, Kamal M., Godbey S, Frank W, Lodenkemper R. Talc induced pleurodesis: role of basic fibroblast growth factor (bFGF). *Eur Respir J.* 1997; 10:403S.
- Whitlow C, Craig R., Brady K, Hetz S. Thoracoscopic pleurodesis with minocycline vs talc in the porcine model. *Surgical Endoscopy.* 1996; 10:1057-1059.
- Light RW. Diseases of the pleura: the use of talc for pleurodesis. *Current Opinion in Pulmonary Medicine.* 2000; 6(4):255-258.
- Brant A, Eaton T. Serious complications with talc slurry pleurodesis. *Respirology.* 2001; 6:181-185.
- Rehse D, Aye R, Florence M. Respiratory failure following talc pleurodesis. *Am J Surgery.* 1999; 177(5):437-440.
- Viallat J, Rey F, Astoul P, Boutin C. Thoracoscopic talc poudrage pleurodesis for malignant effusions: a review of 360 cases. *Chest.* 1996; 110(6):1387-1393.
- Milanez de Campos J, Vargas F de Campos, Werebe E, Cardoso P, Teixeira L, Jatene F, Light R. Thoracoscopy talc poudrage: a 15-year experience. *Chest.* 2001; 119(3):801-806.
- Allen MS, Deschamps C, Jones DM, et al. Video-Assisted Thoracic Surgical Procedures: The Mayo Experience. *Mayo Clinic Proceedings.* 1996; 71(4):351-359.
- Kennedy L, Rusch VW, Strange C, et al. Pleurodesis using talc slurry. *Chest.* 1994; 106:342-346.
- Cardillo G, Facciolo F, Carbone L, Regal M, Corzani F, Ricci A., Di Martino M., Martelli M. Long-term follow-up of video-assisted talc pleurodesis in malignant recurrent pleural effusion. *Eur J Cardio-Thoracic Surg.* 2002; 21:302-306.
- Rinaldo JE, Owens GR, Rogers RM. Adult respiratory distress syndrome following intrapleural instillation of talc. *J Thorac Cardiovasc Surg.* 1983; 85:523-526.
- Aelony Y, King R, Boutin C. Thoracoscopic talc poudrage pleurodesis for chronic recurrent pleural effusions. *Ann Intern Med.* 1991; 115:778-782.
- Colt H, Russack V, Chiu Y, Konopka R, Chiles P, Pedersen C, Kapelanski D. A comparison of thoracoscopic talc insufflation, slurry and mechanical abrasion pleurodesis. *Chest.* 1997; 111(2):442-448.
- Kennedy L, Harley RA, Sahn SA, Strange C. Talc slurry pleurodesis: pleural fluid and histologic analysis. *Chest.* 1995; 107:1707-1712.
- Werebe EC, Pazetti R, De Campos JRM, et al. Systemic distribution of talc after intrapleural administration in rats. *Chest.* 1999; 115:190-193.